

## CASE REPORT

## Surfactant dysfunction and neurodevelopmental delay: a new ABCA3 mutation

Federica Plebani<sup>1</sup>, Chiara Luini<sup>2,\*</sup>, Ilia Bresesti<sup>1</sup>, Daniela Simoncini<sup>2</sup>, Massimo Agosti<sup>1,2</sup>

**\* Correspondence to:**

chiara.luini@asst-settelaghi.it. ORCID: <https://orcid.org/0000-0002-3109-122X>

**Doi**

10.56164/PediatrRespirJ.2023.21

<sup>1</sup> Department of Pediatrics, F. Del Ponte Hospital, University of Insubria, Varese, Italy

<sup>2</sup> Department of Pediatrics, F. Del Ponte Hospital, Varese, Italy

**ABSTRACT**

ABCA3 is a transmembrane protein found on the limiting membrane of lamellar bodies of alveolar type II cells. Its role is the transport of phospholipids for surfactant production. Over 200 ABCA3 mutations are known to compromise ABCA3 functions and bring to different phenotypes, from neonatal respiratory distress syndrome to childhood or adult diffuse interstitial lung diseases.

We report the case of a 19-month-old girl, born at term age, developing respiratory distress six hours after birth. During the first months of life, she developed recurrent long-lasting and oxygen-dependent lower respiratory tract infections, failure to thrive and neurodevelopmental delay. Because a surfactant deficiency was hypothesized, the four genes responsible for primary surfactant dysfunction were analyzed by Next Generation Sequencing. Two mutations were found in the ABCA3 gene (c.2888A > G and c.4714C > T), one inherited from each parent.

To our knowledge, there is no previous reporting of correlation between ABCA3 mutation and neurodevelopmental delay. Neurological abnormalities are instead related to another surfactant dysfunction, caused by NKX2-1 gene mutation. Further cases and accurate genetic diagnosis could be useful to validate this new correlation.

**IMPACT STATEMENT:** ABCA3 is correlated to surfactant dysfunction and respiratory diseases. We present a case report in which surfactant dysfunction combines to mild neurodevelopmental delay, in a patient carrier of compound heterozygosity never described before on ABCA3 gene (c.2888A>G and c.4714C>T).

**CASE REPORT**

C.C. is a 19-month-old girl with recurrent respiratory distress due to long-lasting and oxygen-dependent lower respiratory tract infections, failure to thrive and neurodevelopmental delay.

She is a female twin born at 38 weeks of gestational age by elective caesarean delivery in dichorionic diamniotic twin pregnancy. Neither consanguinity nor other relevant illnesses were reported in her family history. Apgar score was 10-10. Weight (2900 gr) and length (48 cm) were appropriate for gestational age. Six hours after birth the infant developed RDS, initially managed with continuous positive airway pressure. Because of neonatal RDS stage II-III at chest x-rays, surfactant was administered. On day two after birth, clinical conditions got worse,

**KEY WORDS**

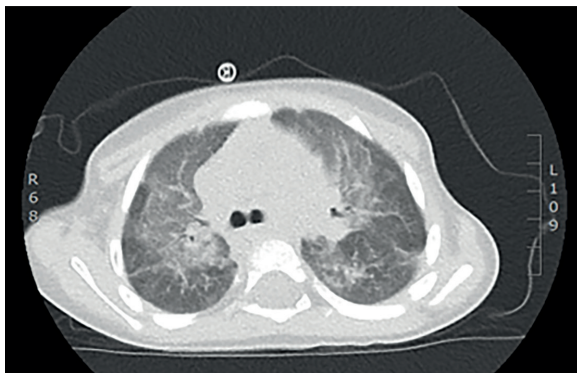
*ABCA3 mutations; surfactant dysfunction; neurodevelopmental delay; case report.*

and the baby was intubated. The patient was extubated after 6 days, and oxygen support was suspended only after 33 days.

The baby also presented hypotonia and neurodevelopmental delay from birth, with no anomalies at cranial ultrasound. Neurodevelopmental delay was confirmed in the next months. She reached sitting position at 12 months, with no capacity of quadruped and crawling at 13-months-old and poor lallation. Brain MRI performed at 13 months was normal. So CGH-array (Comparative Genomic Hybridization Array) was performed and two variants of uncertain significance – maybe related to restless leg syndrome – were found. Now, at 19-months-old, she is not able to stand and walk and the lallation is still strictly poor.

She suffered for lower respiratory tract infections and required six hospitalizations for respiratory support. Even without acute infection, the patient presented polypnea with 30 to 50 breaths per minute respiratory rate, mild subcostal retractions and 93 to 95% peripheral oxygen saturation. The chest x-rays and chest ultrasounds always showed interstitial lung pattern on upper lobes and even peribronchial consolidation with air-trapping. The chest tomography (executed at 15-month-old during a long-lasting infection) showed ground glass opacities and parenchymal consolidations (**Figure 1**).

During hospitalization, she was administered antibiotics, systemic and inhaled corticosteroids, and oxygen support (mainly through high-flow nasal cannula). Multiple investigations were performed (all unremarkable): cystic fibrosis genes mutations, alpha-1 antitrypsin level, lymphocyte typing, immunoglobulin and thyroid hormones levels, transglutaminase Ab, hemogasanalysis,



**Figure 1.** Chest tomography at 15 months.

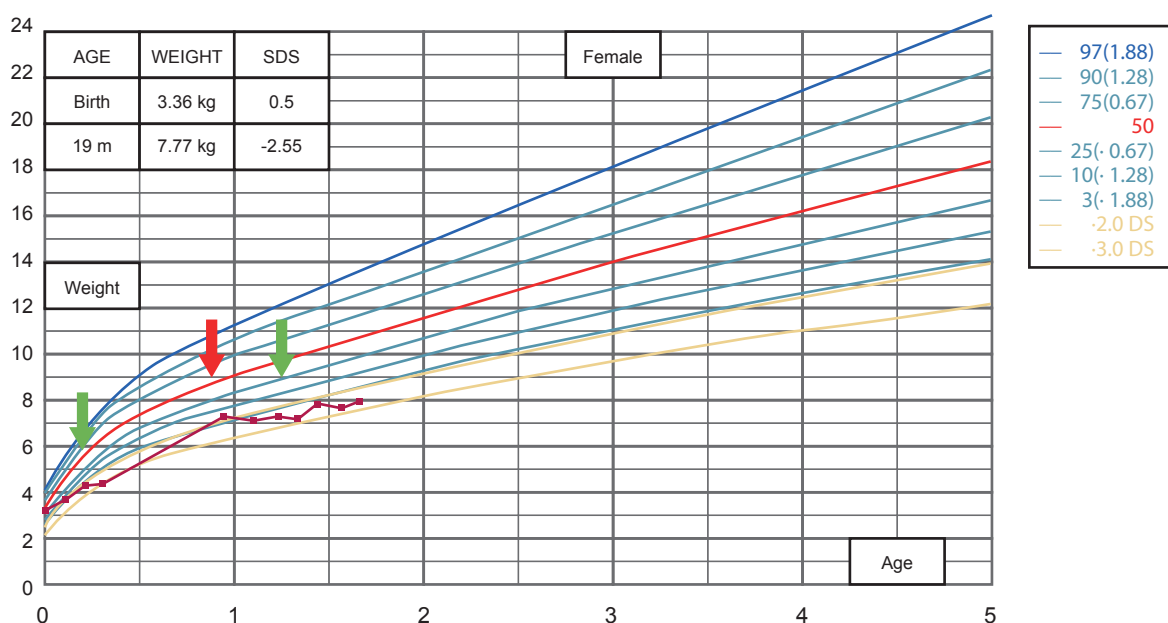
lactate-to-pyruvate ratio, stool elastase. Because of failure to thrive milk protein free diet was started twice, at 3 months and 15 months, with partial response (**Figure 2**). At the end we required blood DNA analysis of four genes by Next Generation Sequencing (SFTPC, SFTPB, NKX2-1, ABCA3), because a genetic surfactant deficiency was supposed. The analysis revealed in trans compound heterozygosity for ABCA3 mutations: c.2888A>G on exon 21, inherited from mother and c.4714C>T on exon 30, inherited from father. No mutation was found in other surfactant protein genes (SFTPC, SFTPB, NKX2-1).

After diagnosis, she started steroid therapy with prednisone 1 mg/kg, with good clinical response and reduction of hospitalization for lower tract respiratory infections.

## DISCUSSION

ABCA3 gene mutations have been associated with RDS and pediatric ILD (5, 6). Correlation between genotype and phenotype is already known. Patients with null/null mutations have poor prognosis: generally, they present RDS at birth and die or undergo lung transplantation before 1 year of age. The outcome of subjects with null/other and other/other genotypes is more challenging (7). The most common ABCA3 mutation is p.Glu292Val (or p.E292V, c.875 A>T)(5, 8, 9). To our knowledge this is the first time these mutations have been reported. Flamein *et al.* reported that the c.2888A>G mutation on a single allele is related to death for neonatal RDS (10). In NHLBI Exome Variant Server c.288A>G mutation is not reported, while c.4714C>T mutation is reported as a coding-synonymous mutation. COSMIC (Catalogue Of Somatic Mutations In Cancer) reported c.4714C>T mutation as pathogenic (score 0.91 FATHMM prediction).

Since our patient presented ILD, poor growth could be explained by increased energy consumption due to increased respiratory work and recurrent infections. Cow's milk free diet was prescribed twice, with decent weight gain, but persistence of lower respiratory tract infections. Hence, Heiner syndrome was excluded (11). She also presented neurodevelopmental delay. To our knowledge, there's no evidence about ABCA3 compound heterozygous mutations related to neurological problems.



**Figure 2.** WHO child growth standard. Failure to thrive, from 0.5 SDS of birth, to -2.55 SDS now. Green arrows show the begin of cow-milk-protein free diet, red arrow the suspension. Data are expressed in kg and in years for age. SIEDP Growth Calculator Application.

Neurodevelopmental delay and muscular atrophy were described by El Boustany *et al.* in a girl with severe respiratory failure after 4 years of mechanical ventilation through tracheostomy (12). Si *et al.* observed developmental delay of varying severity and poor weight gain in three patients with ABCA3 mutations and they related it to probable chronic illness sequelae (13). Neurological abnormalities and surfactant dysfunction are related when the mutation is on NKX2-1 gene, encoding thyroid transcription factor, resulting in the brain-thyroid-lung syndrome (14-16).

## CONCLUSIONS

Over 200 ABCA3 mutations have been found and related to surfactant dysfunction, leading to a wide clinical spectrum, from neonatal RDS to adult ILD. Our patient, with a compound heterozygosity for ABCA3 mutations in trans, presented a new phenotype not previously described, characterized by not only lung disease but also important failure to thrive and neurodevelopmental delay. To our knowledge, the correlation between ABCA3 mutation and neurodevelopmental delay hasn't been described yet. Further cases and accurate genetic diagnosis could be useful to validate this new correlation.

## COMPLIANCE WITH ETHICAL STANDARDS

### Conflict of interests

The Authors have declared no conflict of interests.

### Financial support

There were no institutional or private fundings for this article.

### Author contributions

All the Authors discussed the results and contributed to the final manuscript.

### Ethical approval

#### Human studies and subjects

N/A.

#### Animal studies

N/A.

#### Data sharing and data accessibility

The data underlying this article are available in the article.

### Publication ethics

#### Plagiarism

The contents of the article are original and any overlaps with other articles are by the Authors themselves and appropriately cited.

#### Data falsification and fabrication

All the data correspond to the real.

## REFERENCES

1. Yamano G, Funahashi H, Kawanami O, Zhao LX, Ban N, Uchida Y, et al. ABCA3 is a lamellar body membrane protein in human lung alveolar type II cells. *FEBS Lett.* 2001;508(2):221-5. doi: 10.1016/s0014-5793(01)03056-3.
2. Shulenin S, Nogee LM, Annilo T, Wert SE, Whitsett JA, Dean M. ABCA3 gene mutations in newborns with fatal surfactant deficiency. *N Engl J Med.* 2004;350(13):1296-303. doi: 10.1056/NEJMoa032178.
3. Schindlbeck U, Wittmann T, Höppner S, Kinting S, Liebisch G, Hegermann J, et al. ABCA3 missense mutations causing surfactant dysfunction disorders have distinct cellular phenotypes. *Hum Mutat.* 2018;39(6):841-50. doi: 10.1002/humu.23416.
4. Beers MF, Mulugeta S. The biology of the ABCA3 lipid transporter in lung health and disease. *Cell Tissue Res.* 2017;367(3):481-93. doi: 10.1007/s00441-016-2554-z.
5. Bullard JE, Wert SE, Whitsett JA, Dean M, Nogee LM. ABCA3 mutations associated with pediatric interstitial lung disease. *Am J Respir Crit Care Med.* 2005;172(8):1026-31. doi: 10.1164/rccm.200503-504OC.
6. Singh J, Jaffe A, Schultz A, Selvadurai H. Surfactant protein disorders in childhood interstitial lung disease. *Eur J Pediatr.* 2021;180(9):2711-21. doi: 10.1007/s00431-021-04066-3.
7. Wambach JA, Casey AM, Fishman MP, Wegner DJ, Wert SE, Cole FS, et al. Genotype-phenotype correlations for infants and children with ABCA3 deficiency. *Am J Respir Crit Care Med.* 2014;189(12):1538-43. doi: 10.1164/rccm.201402-0342OC.
8. Garmany TH, Wambach JA, Heins HB, Watkins-Torry JM, Wegner DJ, Bennet K, et al. Population and disease-based prevalence of the common mutations associated with surfactant deficiency. *Pediatr Res.* 2008;63(6):645-9. doi: 10.1203/PDR.0b013e31816fdbeb.
9. Doan ML, Guillerman RP, Dishop MK, Nogee LM, Langston C, Mallory GB, et al. Clinical, radiological and pathological features of ABCA3 mutations in children. *Thorax.* 2008;63(4):366-73. doi: 10.1136/thx.2007.083766.
10. Flamein F, Riffault L, Muselet-Charlier C, Pernelle J, Feldmann D, Jonard L, et al. Molecular and cellular characteristics of ABCA3 mutations associated with diffuse parenchymal lung diseases in children. *Hum Mol Genet.* 2012;21(4):765-75. doi: 10.1093/hmg/ddr508.
11. Moissidis I, Chaidaroon D, Vichyanond P, Bahna SL. Milk-induced pulmonary disease in infants (Heiner syndrome). *Pediatr Allergy Immunol.* 2005;16(6):545-52. doi: 10.1111/j.1399-3038.2005.00291.x.
12. El Boustany P, Epaud R, Grosse C, Barriere F, Grimont-Rolland E, Carsin A, et al. Unusual long survival despite severe lung disease of a child with biallelic loss of function mutations in ABCA-3. *Respir Med Case Rep.* 2018;23:173-5. doi: 10.1016/j.rmcr.2018.03.004.
13. Si X, Steffes LC, Schymick JC, Hazard FK, Tracy MC, Cornfield DN. Three Infants with Pathogenic Variants in the ABCA3 Gene: Presentation, Treatment, and Clinical Course. *J Pediatr.* 2021;231:278-83.e2. doi: 10.1016/j.jpeds.2020.12.055.
14. Breedveld GJ, van Dongen JW, Danesino C, Guala A, Percy AK, Dure LS, et al. Mutations in TITF-1 are associated with benign hereditary chorea. *Hum Mol Genet.* 2002;11(8):971-9. doi: 10.1093/hmg/11.8.971.
15. Guillot L, Carré A, Szinnai G, Castanet M, Tron E, Jaubert F, et al. NKX2-1 mutations leading to surfactant protein promoter dysregulation cause interstitial lung disease in "Brain-Lung-Thyroid Syndrome". *Hum Mutat.* 2010;31(2):E1146-62. doi: 10.1002/humu.21183.
16. Carré A, Szinnai G, Castanet M, Sura-Trueba S, Tron E, Broutin-L'Hermite I, et al. Five new TTF1/NKX2.1 mutations in brain-lung-thyroid syndrome: rescue by PAX8 synergism in one case. *Hum Mol Genet.* 2009;18(12):2266-76. doi: 10.1093/hmg/ddp162.