

## REVIEW

## Congenital pulmonary airways malformation: state of the art review

Rossella Lamberti<sup>1,\*</sup>, Giulia Canali<sup>1</sup>, Alice Romero<sup>1</sup>, Michele Ghezzi<sup>1</sup>, Gian Vincenzo Zuccotti<sup>1,2</sup>, Enza D'Auria<sup>1</sup>

**\* Correspondence to:**

rossella.lamberti@unimi.it. ORCID: <https://orcid.org/0000-0002-4981-5484>

**ABSTRACT**

Congenital pulmonary airway malformations (CPAM) are rare anomalies of the lung development, arising during intra-uterine life. Currently, CPAM are diagnosed prenatally, due to improved imaging techniques. They may be asymptomatic or cause a broad range of symptoms. Symptomatic lesions require treatment, which might be performed during fetal period or after birth. Surgical options vary from minimally invasive to open surgery. Concerning the long-term assessment of respiratory function after lung resection, long-term outcome studies are still lacking. A multi-disciplinary team play an essential role in ensuring that the patients affected by CPAM receive the most appropriate treatment and follow-up to preserve the lung function.

**IMPACT STATEMENT:** The purpose of this revision is to clarify the still controversial management of congenital pulmonary airways malformation in pediatric age.

**INTRODUCTION**

Congenital pulmonary lesions (CLL) are heterogeneous group of rare pulmonary parenchymal abnormalities, including congenital pulmonary airway malformations (CPAM), bronchopulmonary sequestration, bronchial atresia, and congenital lobar emphysema (1).

CPAM are quite rare congenital malformations. Their incidence is between 1:25,000 to 1:35,000 (2). Thanks to increasing prenatal diagnoses, the most recently estimated incidence has increased up to 1 out of 7200 births (3).

CPAM are hamartomatous lesions lined by respiratory epithelium which include cystic and adenomatous elements derived from the tracheal, bronchial, bronchiolar, and alveolar tissue with an abnormal and disorganized growth of the terminal bronchioles (3, 4).

They may be asymptomatic or cause symptoms since the first months of life. These lesions are mainly diagnosed during childhood, even if they are sometimes associated with lung cancer in adults (3).

The underlying pathogenesis require the interplay of multiple regulatory factors, whose involvement in pulmonary malformations still remain uncertain. According to an *environmental hypothesis*, the expression of genetic defects associated to the lung development correlates to a focal and temporary disruption of the lung morphogenesis (4). Supporting this theory, multiple genes involved in cell proliferation/

**Doi**

10.56164/PediatrRespirJ.2023.26

<sup>1</sup> Buzzi Children's Hospital, Milan, Italy

<sup>2</sup> Department of Biomedical and Clinical Sciences, Buzzi Children's Hospital, University of Milan

**KEY WORDS**

*Congenital pulmonary airway malformations; prenatal diagnosis; surgical options; lung function.*

apoptosis could be implicated in the process, including thyroid transcription factor gene (Nkx2), Sonic Hedgehog (SHH), Sprouty 2 (SPRY2), Bone Morphogenetic protein (BMP4), Wnt signaling pathways, transforming growth factor  $\beta$  (TGF $\beta$ ), and fibroblast growth factors 10, 9, and 7 (FGF10, 9, 7) (4). Recently, the *obstructive hypothesis* has been also proposed. According to this hypothesis, the focal obstruction of airways would increase levels of mediators associated to dysplasia found in CPAM (4, 5).

## CLASSIFICATION

The most common classification proposed by Stocker *et al.* (6) initially identified three groups of lesions: type 1, the most frequent form, with large cysts containing mucous cells; type2, characterized by multiple small cysts; type 3, with large solid lesions with mediastinal displacement. In 2001, this classification was updated with new types of lesions such as type 0 (acinar dysplasia) and type 4 with cysts lined by alveolar cells without mucous cells (4).

Recently, this model has been questioned since several studies have suggested that the Stocker's classification may not accurately describe the histopathology of CPAM detected during prenatal period (7, 8). Indeed, congenital lung malformations could usefully be classified into three groups, based on their initial radiographic results (see **Table 1**), congenital solid/cystic lung abnormality, congenital hyperlucent lobe, and congenital small lung, respectively (5, 8).

The first group (congenital solid/cystic lung abnormality) includes congenital pulmonary airway malformations, intra and extra lobar sequestrations, bronchial atresia, bronchogenic cyst, mixed malformations. According to the Author (5), all the masses within this group should be associated to abnormal arterial/venous drainage and might also retain a primitive foregut connection. The second one (congenital hyperlucent lobe) includes congenital lobar emphysema and multi-alveolar lobe. These lesions may have a common etiology that leads to airway obstruction with distal air trapping. Lastly, the third group (congenital small lung) includes lung/lobar agenesis and pulmonary hypoplasia associations (5). In addition, as proposed by Adzick *et al.* (7), a further clinical classification of CPAM is based on the size of the lesions at pre-natal ultrasound, dividing them into macrocystic (75%) with a diameter  $\geq 5$  mm and microcystic with the appearance of a solid mass (25%)  $\leq 5$  mm.

**Table 1.** Simplified classification of congenital lung malformations based on radiographic results.

### Group 1 (Congenital solid/cystic lung malformation)

- Congenital pulmonary airway malformation
- Intra and extra lobar sequestration
- Bronchial atresia
- Bronchogenic cyst
- Mixed malformations

### Group 2 (Congenital hyperlucent lobe)

- Congenital lobar emphysema
- Polyalveolar lobe

### Group 3 (Congenital small lung)

- Lung/lobar agenesis
- Pulmonary hypoplasia associations

## CLINICAL PRESENTATION

Generally, CPAM are asymptomatic malformations (2, 4, 9). Conversely, when the fluid contained in the lesion is replaced with air, the lung compression leads to respiratory distress, immediately after birth or in the first days of life (9). According to recent studies (9), about 25% of asymptomatic patients with prenatal diagnosis of CPAM develop symptoms for the first time around the age of 6-7 months. In addition, CPAM may become symptomatic when lung infection occurs later in life. In fact, the malformation itself becomes a focus of infection, thus making patients more susceptible to recurrent pneumonia in the first months of life (9). The clinical presentation with pneumothorax or hemothorax is very rare but already described in literature (10-12). If early frequent pulmonary infections should arise the clinical suspicion of CPAM, on the other hand wheezing is more frequent in patients antenatally diagnosed and not operated (4).

## DIAGNOSIS

The use of antenatal ultrasound screening has allowed the early detection of congenital lung abnormalities that would not have been diagnosed unless they become symptomatic (5).

The prenatal diagnosis of congenital cystic lung lesions reaches a percentage of 85.7% through ultrasound. The average gestational age at which these malformations can be detected is the second trimester (21-24 weeks), when the CPAM appears as an echogenic mass within the fetal lungs (4).

The role of prenatal magnetic resonance (MRI) is increasingly preponderant, as it is able to detect all types

of fetal malformations with a sensitivity and specificity of 95%. MRI seems to be the best technique to better identify hybrid lesions (4). MRI is also useful in the differential diagnosis between CPAM and other intra-thoracic lesions, allowing to define the exact location of the lesion within the pulmonary lobe and the presence of lung compression (7). However, both prenatal US and MRI show high accuracy in the detection of isolated lung malformations (4, 13).

The initial evaluation should also include fetal echocardiography, since the incidence of structural and functional cardiac anomalies is increased in these patients, affecting prenatal surgical treatment (4, 7).

Once the prenatal diagnosis of CPAM has been made, it is necessary to carry out serial ultrasound screening in order to monitor the possible appearance of hydrops fetalis, mediastinal displacement and esophageal compression (4, 7). Crombleholme et al. developed the CPAM volume ratio (CVR) score to identify fetuses at risk of complications: it is a measure of the lesion volume, normalized by gestational age. Recent studies have shown that a CVR  $\geq 1.6$  was highly predictive of hydrops and that a CVR  $\geq 0.84$  was associated with polyhydramnios and ascites increasing the risk of severe respiratory distress. The purpose of this score is to establish a predictive tool for potential life-threatening complications and to provide an adequate therapeutic approach. In fact, even if 70% of CPAM antenatally diagnosed are asymptomatic at birth, the remaining 30% present with respiratory distress requiring assisted ventilation in 10% of cases (4, 13).

CPAM may undergo spontaneous involution, which has been reported in up to 49% of cases beyond the 28 weeks of gestation (2, 4, 7). Evanescent lung lesions seem to be a frequent finding, especially if they are microcystic and low volume lesions (4,7). Even if we are dealing with a lesion that disappeared during pregnancy, radiological investigations are recommended at birth (7). To avoid exposing the newborn to frequent radiation doses, it would be advisable to carry out a chest X-ray at birth and further scans (X-ray or computed tomography angiography, CTA) within 6 months of life (4). During postnatal follow-up, MRI should be an alternative to a CT scan after surgical resection and even in case of asymptomatic stable lesions (14).

After birth, clinical presentation ranges from being asymptomatic to respiratory failure. In asymptomatic children, the diagnosis of CPAM should be made after

incidental findings on chest radiological imaging performed for other medical indications such as a pulmonary infection or thoracic pain (4, 12).

Moreover, several cases have shown the possibility that lesions firstly defined as CPAM were later diagnosed as pleuropulmonary blastoma (PPB) (15-16), confirming that the misdiagnoses are quite common and that it is essential to plan an adequate follow-up over time, in order to avoid misdiagnoses (12). Numerous studies have confirmed the relationship between DICER1 gene mutations and oncogenesis of a range of neoplasms (17), including PPB and DICER1 genetic analysis should be performed especially in cases of challenging differential diagnosis.

### PRENATAL TREATMENTS

The indications for fetal surgery are extremely rare and based on the pathophysiologic consequences of lung lesions large enough to compromise adjacent organs (14). In fact, mediastinal shift, pulmonary hypoplasia, polyhydramnios, cardiovascular compromise, or esophageal compression require a prenatal management (2). Maternal steroids, thoraco-amniotic shunts, fetal mass resection, and *ex utero intrapartum* treatment (EXIT) procedures play a significant therapeutic role in congenital lung lesions with hydrops, resulting in lower risk of prematurity, less ventilator requirement, and a better outcome, compared to open or minimally invasive fetal surgery (18-22). In macrocystic lesions, thoracocentesis or thoraco-amniotic shunting are useful for both diagnosis and treatment of hydrops. The indications for open fetal surgery are hydrops and signs of evolving fetal heart failure (20). For fetuses with large masses inducing mediastinal shift, when lung development is compatible with life, the EXIT procedure is a therapeutic option performed in highly specialized centers (21). When treatment possibilities are overcome, a therapeutic abortion can be discussed (22).

### POSTNATAL MANAGEMENT

Newborns with respiratory symptoms, including cyst infection, hemorrhage, dyspnea, pneumothorax, nutritional problems, sudden respiratory compromise, and malignant transformation (type 4 CPAM *versus* type I cystic pleuropulmonary blastoma, PPB) require a timely surgical treatment (23-27).

Asymptomatic patients are approximately three quarters of children with a prenatally diagnosed lung malformation.

Prior to discharge, newborns need to do a chest X-ray to establish a baseline for subsequent imaging (24). A multidisciplinary follow-up with a pediatric pulmonologist and surgeon is recommended. The gold standard diagnostic test for evaluating a lung lesion is a chest CTA within six months of life. The role and timing of surgery in asymptomatic lung lesions remains controversial (25).

Surgery in asymptomatic patients can be performed safely with few post-operative complications and planned at a young age in patients with a high risk of developing clinical signs later in life (20). Patients with CPAM appear to have better perioperative outcomes before the beginning of symptoms, including shorter operating times, shorter post-operative mechanical ventilation, shorter chest drainage duration and shorter post-operative hospital stays (23).

The decision to undergo surgery is based on clinical evolution and/or to prevent complications, such as pneumonia refractory to antibiotics due to impaired muco-ciliary clearance of the lesions and tumorigenesis due to chronic inflammation (25, 26).

The best timing for elective surgery of asymptomatic infants is still debated but seems to be between 6 months and 2 years old, in order to maximize the compensatory lung growth and because approximately 25% of originally asymptomatic patients develop symptoms at around the age of 6-7 months (9, 27-29). Indeed, the timing of the surgical treatment depends on the clinical conditions of the patient. In case of respiratory distress, the surgery will be performed urgently, otherwise the surgical treatment can be postponed until 12-18 months of life (23-28).

Currently, thoracoscopy is considered the preferred surgical approach over the standard thoracotomy, with reduction of post-operative complication and musculoskeletal deformities (30-32). Pulmonary resection via conventional open thoracotomy may be performed using a muscle sparing technique, which is associated with relatively lower long-term musculoskeletal morbidity (32).

The thoracoscopic intervention is difficult in neonates because of the small exposure space. Video-assisted thoracoscopic surgery was reported to be safe and effective, even in infants less than 3 months of age when performed in experienced centers (33).

The choice between lobectomy or partial lobectomies (e.g., segmentectomies, wedge resections) should be

guided by the extension of the lesion which should be completely removed, sparing as much lung parenchyma as possible (2, 20, 34).

## NATURAL HISTORY AND CLINICAL OUTCOME

Children with congenital malformations affecting lung development are at risk of short and long-term respiratory complications, especially in the first years of life. At least three quarters of patients with a prenatal diagnosis of CPAM are asymptomatic at birth. For these patients the clinical management is still controversial (34). Given the prognostic implication of neoplastic transformation, the identification of DICER 1 mutations could be useful to identify who undergo early surgery among totally asymptomatic patients (17, 35, 36).

Even if an early resection should lead to a better compensatory growth, surgery is not the universally accepted choice in case of asymptomatic lesions (25). On the other hand, the recurrent infections and the related tissue inflammation are the most important factor in influencing the timing of surgery (36).

As reported by Zeng *et al.*, the early surgical treatment should be performed within 2 years of age, considering the high risk of infection and more invasive surgery (34). Beyond pulmonary infections and reduction of pulmonary function, the risk of malignancy development should be an incentive for prophylactic excision of asymptomatic CPAM (34).

The natural history of patients who did not undergo surgical treatment is poor understood (25, 37). Even if many CPAMs remain asymptomatic for years (38, 39), endorsing a "wait and see" approach, the operative complication rate increases as lesions become symptomatic, thus requiring urgent surgery (37). This evidence could suggest an elective surgical treatment. In case of surgical treatment, early post-surgical complications (e.g., includes pneumothorax, pleural effusion with subcutaneous emphysema and respiratory distress) may not be related to a specific surgical approach or to the surgical technique (40). Long-term complications (e.g., chronic cough, recurrent lower-airway infections, wheezing, poor tolerance to exercise, or orthopedic impairments) show up with high prevalence during post-surgery follow-up (41).

Concerning the long-term assessment of respiratory function of children who underwent surgery for lung resection, the literature shows a lack of long-term out-

come studies into adulthood. Most studies used respiratory function as a surrogate marker for lung growth and volume. Lam *et al.* (32) performed a direct comparison between thoracoscopic and open lobectomy to test for any difference between the surgical approaches, evaluating long term pulmonary function test (PFT). Even if most patients from both groups have normal long term PFT results, up to 10% of them developed subclinical impairment of PFT (restrictive pattern) (32). Generally, Total Lung Capacity (TLC) is preserved at long term follow-up and may even be more than expected. The elevated residual volumes and functional residual capacity found after lobectomy advocates that overexpansion of residual lung may be compensating for loss of tissue and contributing to TLC, rather than true lung growth (42).

**CONCLUSIONS**

Great improvements have been made in the understanding of CPAM features. Its clinical detection is almost done prenatally, even if the diagnosis can be made accidentally in the postnatal period based on respiratory symptoms and radiological imaging (Figure 1). The indication for surgery is widely supported for symptomatic lesions. Conversely, the management of asymptomatic lesions is still debated.

Notably, elective surgery reduces the risk of infections and pneumothorax, improves compensatory lung growth, and prevents the risk of neoplastic degeneration (carcinoma, pleuropulmonary blastoma). A multi-disciplinary team should play an essential role in ensuring that the patients affected by CPAM receive the most appropriate treatment and follow-up to preserve the lung function (Infobox 1).

*Infobox 1. Educational aims.*

**Box 1. Educational Aims**

- CPAM are quite rare congenital malformations
- The diagnosis of congenital cystic lung lesions is almost prenatal
- The decision to undergo surgery in symptomatic patients is based on clinical evolution and/or to prevent complications
- The best timing for surgery of asymptomatic patients is still debated
- A multi-disciplinary team should play an essential role in ensuring that the patients affected by CPAM receive the most appropriate treatment and follow-up to preserve the lung function

**COMPLIANCE WITH ETHICAL STANDARDS**

**Conflict of interests**

The Authors have declared no conflict of interests.

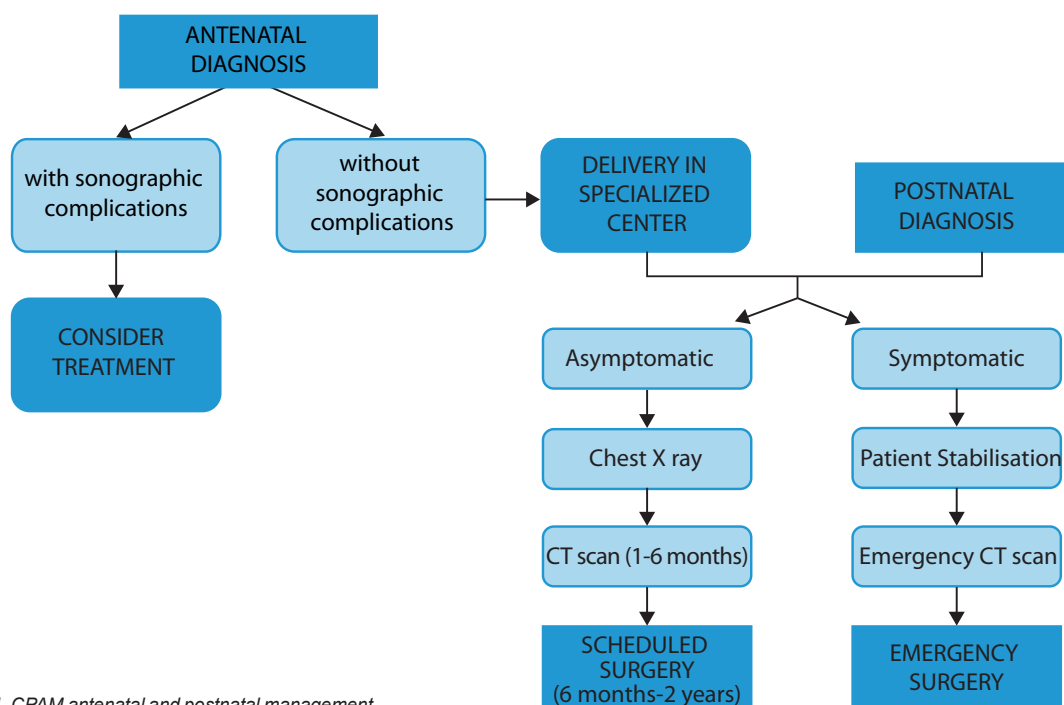


Figure 1. CPAM antenatal and postnatal management.

**Financial support**

There were no institutional or private fundings for this article.

**Author contributions**

RL, MG and ED: conceptualized the study, drafted the initial manuscript, reviewed the literature and critically revised the final manuscript. GC and AR: contributed to the review of the literature. They also actively participated in manuscript drafting, critically reviewing it. All Authors read and approved the final manuscript as submitted and agree to be accountable for all aspects of the work.

**Ethical approval***Human studies and subjects*

N/A.

*Animal studies*

N/A.

*Data sharing and data accessibility*

All the data are available in the article.

**Publication ethics***Plagiarism*

All original studies are cited as appropriate.

*Data falsification and fabrication*

All the data correspond to the real.

**REFERENCES**

- Moyer J, Lee H, Vu L. Thoracoscopic Lobectomy for Congenital Lung Lesions. *Clin Perinatol*. 2017;44(4):781-94. doi: 10.1016/j.clp.2017.08.003.
- Leblanc C, Baron M, Desselas E, Phan MH, Rybak A, Thouvenin G, Lauby C, Irtan S. Congenital pulmonary airway malformations: state-of-the-art review for pediatrician's use. *Eur J Pediatr*. 2017;176(12):1559-71. doi: 10.1007/s00431-017-3032-7.
- Kapralik J, Wayne C, Chan E, Nasr A. Surgical versus conservative management of congenital pulmonary airway malformation in children: A systematic review and meta-analysis. *J Pediatr Surg*. 2016;51(3):508-12. doi: 10.1016/j.jpedsurg.2015.11.022.
- Mehta PA, Sharma G. Congenital Pulmonary Airway Malformation. 2022 Aug 8. In: *StatPearls*. Treasure Island (FL): StatPearls Publishing; 2023.
- Seear M, Townsend J, Hoepker A, Jamieson D, McFadden D, Daigneault P, et al. A review of congenital lung malformations with a simplified classification system for clinical and research use. *Pediatr Surg Int*. 2017;33(6):657-64. doi: 10.1007/s00383-017-4062-y.
- Stocker JT, Madewell JE, Drake RM. Congenital cystic adenomatoid malformation of the lung. Classification and morphologic spectrum. *Hum Pathol*. 1977;8(2):155-71. doi: 10.1016/s0046-8177(77)80078-6.
- Mann S, Wilson RD, Bebbington MW, Adzick NS, Johnson MP. Antenatal diagnosis and management of congenital cystic adenomatoid malformation. *Semin Fetal Neonatal Med*. 2007;12(6):477-81. doi: 10.1016/j.siny.2007.06.009.
- Bush A. Congenital lung disease: a plea for clear thinking and clear nomenclature. *Pediatr Pulmonol*. 2001;32(4):328-37. doi: 10.1002/ppul.1126.
- Kantor N, Wayne C, Nasr A. Symptom development in originally asymptomatic CPAM diagnosed prenatally: a systematic review. *Pediatr Surg Int*. 2018;34(6):613-20. doi: 10.1007/s00383-018-4264-y.
- Adórno IF, Santos RFT, de Faria BB, Marchiori E, Nunes TF. Pleuropulmonary blastoma manifesting as spontaneous pneumothorax: an unusual presentation. *Radiol Bras*. 2019;52(3):202-203. doi: 10.1590/0100-3984.2017.0189.
- Ploenes T, Schildhaus HU, Theegarten D, Stehling F, Dirksen U, Stefani D, et al. Pleuropulmonary blastoma misinterpreted as spontaneous pneumothorax in an infant. *Ann Thorac Surg*. 2020;110(1):e79. doi: 10.1016/j.athoracsur.2020.03.033.
- Lamberti R, Ghezzi M, Riccaboni F, Farolfi A, Zirpoli S, Zengga A, et al. Hypertensive pneumothorax with cystic lesions: Pleuropulmonary blastoma in an infant. *Respir Med Case Rep*. 2022;41:101793. doi: 10.1016/j.rmcr.2022.101793.
- Euser AG, Meyers ML, Zaretsky MV, Crombleholme TM. Comparison of congenital pulmonary airway malformation volume ratios calculated by ultrasound and magnetic resonance imaging. *J Matern Fetal Neonatal Med*. 2016;29(19):3172-7. doi: 10.3109/14767058.2015.1118038.
- David M, Lamas-Pinheiro R, Henriques-Coelho T. Prenatal and Postnatal Management of Congenital Pulmonary Airway Malformation. *Neonatology*. 2016;110(2):101-15. doi: 10.1159/000440894.
- Feinberg A, Hall NJ, Williams GM, Schultz KA, Miniati D, Hill DA, et al. Can congenital pulmonary airway malformation be distinguished from Type I pleuropulmonary blastoma based on clinical and radiological features? *J Pediatr Surg*. 2016;51(1):33-7. doi: 10.1016/j.jpedsurg.2015.10.019.
- Oliveira C, Himidan S, Pastor AC, Nasr A, Manson D, Taylor G, et al. Discriminating preoperative features of pleuropulmonary blastomas (PPB) from congenital cystic adenomatoid malformations (CCAM): a retrospective, age-matched study. *Eur J Pediatr Surg*. 2011;21:2-7. doi: 10.1055/s-0030-1267923.
- González IA, Stewart DR, Schultz KAP, Field AP, Hill DA, Dehner LP. DICER1 tumor predisposition syndrome: an evolving story initiated with the pleuropulmonary blastoma. *Mod Pathol*. 2022;35(1):4-22. doi: 10.1038/s41379-021-00905-8.

18. Mehl SC, Short WD, Kinley A, Olutoye OO 2<sup>nd</sup>, Lee TC, Keswani SG, King A. Maternal Steroids in High-Risk Congenital Lung Malformations. *J Surg Res.* 2022;280:312-9. doi: 10.1016/j.jss.2022.07.035.
19. Loh KC, Jelin E, Hirose S, Feldstein V, Goldstein R, Lee H. Microcystic congenital pulmonary airway malformation with hydrops fetalis: steroids vs. open fetal resection. *J Pediatr Surg.* 2012;47(1):36-9. doi: 10.1016/j.jpedsurg.2011.10.015.
20. Verhallemans Q, Richter J, Proesmans M, Decaluwé H, Debeer A, Van Raemdonck D. Congenital cystic adenomatoid malformations of the lung: a retrospective study of diagnosis, treatment strategy and postoperative morbidity in surgically treated patients. *Eur J Cardiothorac Surg.* 2022;62(4):ezac464. doi: 10.1093/ejcts/ezac464.
21. Cass DL, Olutoye OO, Cassady CI, Zamora IJ, Ivey RT, Ayres NA, et al. EXIT-to-resection for fetuses with large lung masses and persistent mediastinal compression near birth. *J Pediatr Surg.* 2013;48(1):138-44. doi: 10.1016/j.jpedsurg.2012.10.067.
22. Ruchonnet-Mettrailler I, Leroy-Terquem E, Stirnemann J, Cros P, Ducoin H, Hadchouel A, et al. Neonatal outcomes of prenatally diagnosed congenital pulmonary malformations. *Pediatrics.* 2014;133(5):e1285-91. doi: 10.1542/peds.2013-2986.
23. Kunisaki SM, Saito JM, Fallat ME, Peter SDS, Lal DR, Karmakar M, et al.; Midwest Pediatric Surgery Consortium. Fetal Risk Stratification and Outcomes in Children with Prenatally Diagnosed Lung Malformations: Results from a Multi-Institutional Research Collaborative. *Ann Surg.* 2022;276(5):e622-e630. doi: 10.1097/SLA.0000000000004566.
24. Calvert JK, Lakhoo K. Antenatally suspected congenital cystic adenomatoid malformation of the lung: postnatal investigation and timing of surgery. *J Pediatr Surg.* 2007;42(2):411-4. doi: 10.1016/j.jpedsurg.2006.10.015.
25. Criss CN, Musili N, Matusko N, Baker S, Geiger JD, Kunisaki SM. Asymptomatic congenital lung malformations: Is nonoperative management a viable alternative? *J Pediatr Surg.* 2018;53(6):1092-7. doi: 10.1016/j.jpedsurg.2018.02.065.
26. Pelizzo G, Avanzini MA, Folini M, Bussani R, Mantelli M, Croce S, et al. CPAM type 2-derived mesenchymal stem cells: Malignancy risk study in a 14-month-old boy. *Pediatr Pulmonol.* 2017;52(8):990-9. doi: 10.1002/ppul.23734.
27. Kunisaki SM, Saito JM, Fallat ME, St Peter SD, Lal DR, Johnson KN, et al.; Midwest Pediatric Surgery Consortium. Development of a multi-institutional registry for children with operative congenital lung malformations. *J Pediatr Surg.* 2020;55(7):1313-8. doi: 10.1016/j.jpedsurg.2019.01.058.
28. Eber E. Antenatal diagnosis of congenital thoracic malformations: early surgery, late surgery, or no surgery? *Semin Respir Crit Care Med.* 2007;28(3):355-66. doi: 10.1055/s-2007-981656.
29. Jelin EB, O'Hare EM, Jancelewicz T, Nasr I, Boss E, Rhee DS. Optimal timing for elective resection of asymptomatic congenital pulmonary airway malformations. *J Pediatr Surg.* 2018;53(5):1001-5. doi: 10.1016/j.jpedsurg.2018.02.032.
30. Bawazir OA. Thoracoscopy in pediatrics: Surgical perspectives. *Ann Thorac Med.* 2019;14(4):239-47. doi: 10.4103/atm.ATM\_114\_19.
31. Adams S, Jobson M, Sangnawakij P, Heetun A, Thaventhiran A, Johal N, et al. Does thoracoscopy have advantages over open surgery for asymptomatic congenital lung malformations? An analysis of 1626 resections. *J Pediatr Surg.* 2017;52(2):247-51. doi: 10.1016/j.jpedsurg.2016.11.014.
32. Lam FKF, Lau CT, Yu MO, Wong KKY. Comparison of thoracoscopy vs. thoracotomy on musculoskeletal outcomes of children with congenital pulmonary airway malformation (CPAM). *J Pediatr Surg.* 2021;56(10):1732-6. doi: 10.1016/j.jpedsurg.2021.01.028.
33. Tsai AY, Liechty KW, Hedrick HL, Bebbington M, Wilson RD, Johnson MP, et al. Outcomes after postnatal resection of prenatally diagnosed asymptomatic cystic lung lesions. *J Pediatr Surg.* 2008;43(3):513-7. doi: 10.1016/j.jpedsurg.2007.10.032.
34. Zeng J, Liang J, Li L, Liu W, Tang J, Yin X, et al. Surgical Treatment for Asymptomatic Congenital Pulmonary Airway Malformations in Children: Waiting or Not? *Eur J Pediatr Surg.* 2021;31(6):509-17. doi: 10.1055/s-0040-1719057.
35. de Kock L, Wu MK, Foulkes WD. Ten years of DICER1 mutations: Provenance, distribution, and associated phenotypes. *Hum Mutat.* 2019;40(11):1939-53. doi: 10.1002/humu.23877.
36. Brcic L, Fakler F, Eidenhammer S, Thueringer A, Kashofer K, Kulka J, et al. Pleuropulmonary blastoma type I might arise in congenital pulmonary airway malformation type 4 by acquiring a Dicer 1 mutation. *Virchows Arch.* 2020;477(3):375-82. doi: 10.1007/s00428-020-02789-6.
37. Makhijani AV, Wong FY. Conservative post-natal management of antenatally diagnosed congenital pulmonary airway malformations. *J Paediatr Child Health.* 2018;54(3):267-71. doi: 10.1111/jpc.13727.
38. Durell J, Thakkar H, Gould S, Fowler D, Lakhoo K. Pathology of asymptomatic, prenatally diagnosed cystic lung malformations. *J Pediatr Surg.* 2016;51(2):231-5. doi: 10.1016/j.jpedsurg.2015.10.061.
39. Style CC, Cass DL, Verla MA, Cruz SM, Lau PE, Lee TC, et al. Early vs. late resection of asymptomatic congenital lung malformations. *J Pediatr Surg.* 2019;54(01):70-4. doi: 10.1016/j.jpedsurg.2018.10.035.
40. Farolfi A, Ghezzi M, Calcaterra V, Riccipetoni G, Pelizzo G, Costanzo S, et al. Congenital Lung Malformations: Clinical and Functional Respiratory Outcomes after Surgery. *Children (Basel).* 2022;9(12):1881. doi: 10.3390/children9121881.
41. Calzolari F, Braguglia A, Valfrè L, Dotta A, Bagolan P, Morini F. Outcome of infants operated on for congenital pulmonary malformations. *Pediatr Pulmonol.* 2016;51(12):1367-72. doi: 10.1002/ppul.23472.
42. Hall NJ, Stanton MP. Long-term outcomes of congenital lung malformations. *Semin Pediatr Surg.* 2017;26(5):311-6. doi: 10.1053/j.sempedsurg.2017.09.001.