

CASE REPORT

Congenital bronchial stenosis: a case report of an unusual diagnosis and its management

Laura Venditto¹, Giuliana Ferrante^{1,*}, Laura Tenero¹, Antonella Coretti², Francesca Petreschi², Veronica Bordonaro³, Renato Cutrera², Adriano Carotti⁴, Giorgio Piacentini¹

Correspondence to:

Giuliana.ferrante@univr.it. ORCID: <https://orcid.org/0000-0001-9917-2387>

ABSTRACT

Congenital bronchial stenosis is a rare bronchopulmonary anomaly characterized by significantly narrowing or blindly ending of a segmental or lobar bronchus, typically limited to a few rings, caused by developmental anomalies in the cartilaginous exoskeleton.

We describe a case of a six-month-old male infant with intermittent wheezing present since birth, with no signs of respiratory distress, which seemed to not respond to bronchodilators and to appear more evident with crying and during common colds.

He didn't present respiratory distress, but an expiratory wheezing was heard. A tidal flow-volume loop was recorded and appeared slightly deflected during the expiratory phase, with a normal tidal volume. A bronchoscopy detected a stenosis of the left main bronchus, confirmed by the chest computed tomography (CT). The patient underwent surgical treatment, consisting of resection of the stenotic tract and tracheobronchial anastomosis with a good result.

Congenital bronchial stenosis should be considered in newborns and infants with persistent wheezing that doesn't respond to bronchodilators; a tidal flow-volume loop could suggest the diagnosis, which should be confirmed with chest CT and bronchoscopy.

IMPACT STATEMENT: A case report of congenital bronchial stenosis, with the aim to review its diagnosis and management.

INTRODUCTION

The occurrence of wheezing in infants can be referred to a broad list of differential diagnoses, that include airways or vascular anomalies, cardiac, metabolic, and infectious diseases. A rare cause of persistent wheezing in infants could be congenital bronchial stenosis (CBS). CBS is a bronchial anomaly characterized by a significant narrowing of a segmental or lobar bronchus, usually limited to a few cartilaginous rings, caused by developmental anomalies in the cartilaginous exoskeleton (1) or by compressive vascular anomaly, cardiac anomaly, or congenital pulmonary cyst (2).

Doi

10.56164/PediatrRespirJ.2023.36

¹ Pediatric Division Department of Surgery, Dentistry, Gynecology and Pediatrics, University of Verona, Verona, Italy

² Pediatric Pulmonology and Cystic Fibrosis Unit, Bambino Gesù Pediatric Hospital, IRCCS, Rome, Italy

³ Advanced Cardiovascular Radiology Unit, Department of Radiology and Bioimaging, Bambino Gesù Pediatric Hospital, IRCCS, Rome, Italy

⁴ Unit of Complex Cardiac Surgery, Bambino Gesù Pediatric Hospital, IRCCS, Rome, Italy

ABBREVIATIONS

CBS: Congenital Bronchial Stenosis

CTS: Congenital Tracheal Stenosis

CT: Computed Tomography

KEY WORDS

Congenital bronchial stenosis; tidal breathing flow volume loop; bronchoplasty; infant; case report.

This report describes the case of a six-month-old boy who presented intermittent wheezing, and who was found to have congenital bronchial stenosis which was surgically corrected.

CASE REPORT

A six-month-old infant was referred to the pediatric respiratory outpatient clinic with a history of expiratory wheezing since birth, with no signs of respiratory distress, which seemed to not respond to bronchodilators and to appear more evident with crying and during common colds.

He was delivered at term; he had clinodactyly of the second finger of the left hand, waiting for surgical correction. His developmental history and his growth were on average; he was bottle-fed with no signs suggestive of aspiration. His family history was unremarkable.

At the examination, he was afebrile, his height was 65 cm (-1 Standard Deviation (SD)), and his weight was 7.4 kg (-1 SD).

Oxygen saturation was 97% in room air. No signs of respiratory distress were present. At chest auscultation, bilateral wheezing was heard. The remaining physical examination was unremarkable, apart from mild pectus excavatum. A tidal flow-volume loop while asleep was recorded (**Figure 1**), which appeared slightly deflected during the expiratory phase with a normal tidal volume (8 mL/kg).

The patient was electively admitted to the ward. A chest x-ray resulted normal; flexible bronchoscopy demonstrated severe stenosis of the left main bronchus, which was later confirmed by CT scan, showing a stenosis of 1.4 mm for a length of 2.2 mm with initial hyperinflation of the left lung. To avoid associated malformations, we performed the echocardiography and

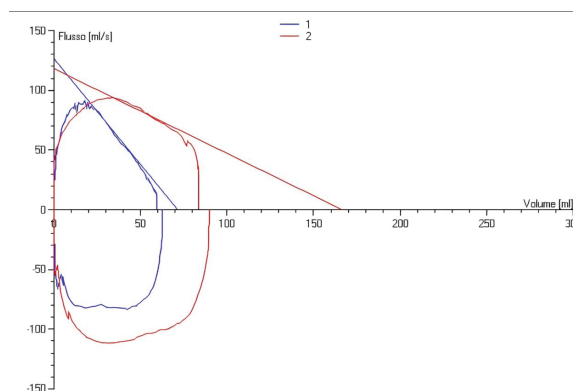


Figure 1. Tidal flow-volume loop recorded while asleep with slight deflection during the expiratory phase with a normal tidal volume (8 mL/kg); tidal flow-volume loop recorded while asleep after surgery showed a normal morphology with a normal tidal volume (9.8 mL/kg).

the ultrasound of the abdomen, which were normal. At 8 months of age, the patient was admitted to another tertiary hospital. At admission, sleep studies were performed showing no desaturations or apnea. After a multidisciplinary discussion, a CT scan with contrast medium under general anesthesia was repeated allowing to exclude any vascular malformation that could have determined the stenosis; the 3D volume rendering reconstruction and the virtual bronchoscopy reconstruction (**Figure 2A, B, C**) showed an expiratory collapse of the bronchial lumen, suggestive of associated bronchomalacia.

Rigid bronchoscopy was repeated (**Figure 3A**) and a 2.8 mm flexible endoscope was able to overcome the stenosis and explore the bronchial system beyond the stenosis, which appeared normal.

The case was discussed by a multidisciplinary board with the decision to proceed surgically.

After midline sternotomy, the patient was placed on normothermic cardiopulmonary bypass with the

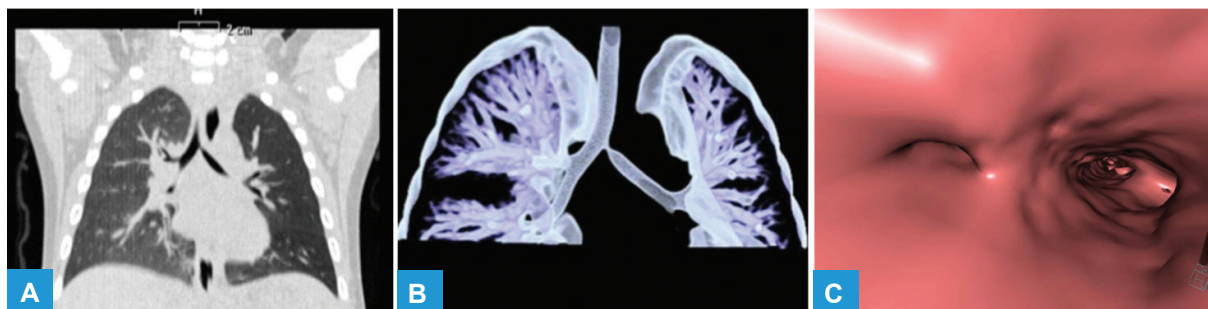


Figure 2. (A) Coronal non-enhanced CT image with lung window showing stenosis of the proximal left main bronchus and hyperinflation of the right lung; (B) 3D volume rendering reconstruction of the tracheobronchial tree; (C) virtual bronchoscopy reconstruction demonstrating marked narrowing of the left main bronchus lumen.

beating heart by right atrial and ascending aortic cannulation. The carina and left mainstem bronchus were exposed by dissecting the transverse sinus of the pericardium and removing the subcarinal lymph nodes. Hence a left bronchial transection distal to the site of the stenosis and an oblique section at the origin of the left main bronchus extended to the carina and distal tracheal portion were made. Finally, a terminal-lateral tracheobronchial anastomosis was performed using a running resorbable 6-0 polydioxanone (PDS) suture. An intraoperative fiberoptic control confirmed a satisfactory anastomosis with a wide and patent bronchus (**Figure 3B**), and the cardiac procedure of disconnection from bypass was undertaken. Mediastinal and right pleural drainages were inserted. The patient was extubated after the procedure and remained stable in high-flow-nasal-cannula. On postoperative day 2, he was started on empirical antibiotic therapy with ceftazidime for a right lower lobe pneumonia with effusion. He was discharged on postoperative day 8 with the resolution of the effusion. Audiological assessment and eye examination resulted normal.

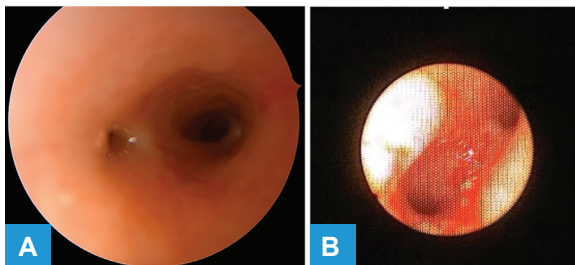


Figure 3. (A) Rigid bronchoscopy showing a significant stenosis of the left main bronchus; (B) intraoperative fiberoptic control showing a wide and patent left main bronchus.

Two months after surgery, he presented intermittent noisy breathing and inconstant inspiratory stridor, with no signs of respiratory distress or infections. A bronchoscopy under general anesthesia was then performed, revealing mild laryngomalacia and raising suspicion of partial left vocal cord paralysis.

Moreover, a tidal flow-volume-loop was recorded, showing no alterations with a normal tidal volume (**Figure 1**). The patient is undergoing respiratory follow-up with tidal flow-volume loops, and a chest CT will be repeated one year after surgery.

DISCUSSION

Bronchial stenosis could be acquired or congenital. Acquired stenosis in children is usually caused by infection, traumatic granulomas due to chronic intubation, lymph node enlargement, atelectasis (3), tracheobronchomalacia and excessive dynamic airway collapse (4). In particular, in a retrospective study (5) the most common causes of endobronchial obstructions detected in 256 pediatric patients were aspirated foreign bodies (35.9%), endobronchial tuberculosis (31.6%), mucous plugs (16.7%) and granulation scars (6%) and other rare pathologies found were hydatid cysts, hemangiomas, tumors, submucosal nodules, and polyps.

CBS is rare, it can be occasionally diagnosed prenatally (6), but usually it becomes more apparent in the neonatal period (7).

CBS usually involves the left main bronchus (2). Other structural anomalies may also be found including subglottic stenosis, tracheoesophageal fistula, and esophageal atresia (1).

Symptoms can vary, based on the location of the stenosis and the residual lumen (2). In fact, CBS determines a “ball-valve” mechanism with ipsilateral air trapping and lung distention (7) leading to diminished unilateral breath sounds at the physical examination; inspiratory and expiratory stridor can also be present, due to fixed airway obstruction (7) as observed in our patient, which not respond to beta2agonists (7). Other clinical signs include “barking” or brassy cough, “washing machine” airway sounds, cyanosis, and breathing spells (2). In some cases, especially when tracheal stenosis is associated, CBS could present at birth with significant respiratory distress, needing non-invasive or invasive respiratory support (7). Sometimes, patients could present only subtle symptoms of airflow limitation as wheezing and increased work of breathing, especially near the end of the first year of life when physical activity increases, until late childhood or early adolescence, when they tend to develop exercise-associated respiratory difficulties and, consequently, a CBS could be found as an incidental finding during the diagnostic work-up (8).

There is no consensus on the diagnostic approach. Since the same symptoms could be a sign of congenital tracheal stenosis (CTS), it is more cautious to perform a rigid bronchoscopy under general anesthesia

(8) with extreme care, since a mucosal lesion could precipitate edema, leading to a critical obstruction. Even though the stenosis could be detected by a CT scan, the diagnosis is made usually by bronchoscopy, because it provides dynamic information about malacia (1), along with the location, the extension, and the severity (2) of the stenosis.

Other approaches include the virtual endoscopy, which evaluates distal airway anatomy using high-resolution multirow detector computed tomography (CT) scanning to obtain high-resolution 3-dimensional endoluminal images to the level of the segmental bronchi (5) distal to the stenosis which are impassable for flexible bronchoscopy. Virtual endoscopy has the advantage that it can be performed without general anesthesia, and there is no direct invasion of the airways (9). Moreover, it could be used as a complementary technique for the planning of the flexible bronchoscopy, in patients who could not tolerate the bronchoscopy, and for the follow-up of the stenosis (10).

In a retrospective study (11) patients with CBS were found to have similar high comorbidity of cardiovascular anomalies as children with CTS (55.6%), such as pulmonary artery sling, ventricular septum defect, atrial septum defect, patent *ductus arteriosus*. In view of the high proportion of patients with other congenital vascular and cardiac anomalies, echocardiography should be performed to rule out any cardiac defect, along with a contrast CT scan with 3D reconstruction, that will better depict the anatomy of the airways, the parenchyma, and the vessels (2), allowing to characterize any vascular rings as in the case presented. It should be noted that CT frequently underestimates the degree and length of airway narrowing (8). Magnetic resonance imaging enables the assessment of the vascular structures (2), and it has been found to be equally sensitive to CT to detect congenital cardiovascular malformations associated with airway pathologies without any radiation exposure (12).

Furthermore, 3-dimensional printing in case of complex airway anomalies could help in the planning of the surgical approach and educate care providers and family members (13).

Additionally, our patient had *pectus excavatum*. The association between chest deformities and bronchial stenosis is described in the literature (14-16). It has

been suggested that the costosternal retraction can be the consequence of the increased intrathoracic pressure during expiration to overcome the airway obstruction due to the CBS (14) and usually the deeper impression corresponds to the side of the CBS. Accordingly to this hypothesis, the *pectus excavatum* of the patient nearly resolved at the 6-month after-surgery follow-up evaluation. However, it is questionable whether *pectus excavatum* is solely due to CBS. CBS, in fact, can be also caused by an abnormal thoracic configuration (17) due to complex mechanisms of vascular compression (15). Based on the clinical presentation, it could be useful to perform a full genotyping as suggested by some Authors (1), along with further diagnostic work-up, especially in the presence of features suggesting skeletal dysplasia (18).

CBS should be managed at major tertiary centers with experience in complex airway malformation, involving a multidisciplinary team including cardiothoracic surgeons, otolaryngologists, cardiologists, pulmonologists, and anesthesiologists (8).

The surgical approaches vary in the literature and are better characterized for CTS rather than CBS. However, they should be tailored to the patient (19) and the presence of other anatomical abnormalities. Surgery includes resection and reconstruction, and bronchoplastic techniques (20, 21); nonetheless, both are complex, especially in infants because of the smaller size of the airways (2). The post-operative bronchoscopy could show granulation tissue, mild restenosis, or formal scarring that could be treated with balloon dilatation (1); in these cases, it would be desirable to avoid laser techniques that could induce thermal damage to the tissue with the consequent risk of restenosis (1). Another postoperative complication is bronchial malacia, which could be addressed with a stent placement (22).

Ultimately, given the lack of international consensus on CBS diagnosis and management, raising awareness of this condition is important to allow a prompt diagnosis.

KEY TAKEAWAYS

- CBS is a rare malformation usually diagnosed during the neonatal period, but even in late childhood.

- Presentation varies from unexplained neonatal respiratory distress to a late presentation with inspiratory-expiratory stridor, wheezing, increased work of breathing, noisy breathing, cyanosis, breath-spells, and apnea.
- Usual findings at chest examination are diminished unilateral breath sounds, wheezing or stridor.
- Chest X-rays usually show ipsilateral lung hyperinflation or could result in normal.
- CBS is usually diagnosed with bronchoscopy, which should be performed carefully to avoid any tissue damage.
- Echocardiography and contrast CT are needed to evaluate the presence of congenital cardiovascular malformations such as vascular rings that are usually associated with CBS; 3D CT reconstruction and virtual bronchoscopy are helpful and complementary to bronchoscopy to assess distal airways and for surgical planning.
- Generally, CBS is managed surgically; the approach should be tailored to the patient and discussed within a multidisciplinary team.
- Close follow-up with monitoring for postoperative complications, and parental education, can impact the outcome of the patient.

COMPLIANCE WITH ETHICAL STANDARDS

Conflict of interests

The Authors have declared no conflict of interests.

Financial support

There were no institutional or private fundings for this article.

Author contributions

LV: writing the original draft; GF, LT, ANC, FP, VB, ADC: writing, review, and editing; ADC: supervision; RC, GP: conceptualization, and supervision.

Ethical approval

Human studies and subjects

The caregivers gave their informed consent to the submission of this manuscript, that followed the ethical standards established in the Declaration of Helsinki.

Data sharing and data accessibility

N/A.

Publication ethics

Plagiarism

Authors declare no potentially overlapping publications with the content of this manuscript and all original studies are cited as appropriate.

Data falsification and fabrication

All the data correspond to the real.

REFERENCES

- Hewitt RJ, Butler CR, Maughan EF, Elliott MJ. Congenital tracheobronchial stenosis. *Semin Pediatr Surg.* 2016;25(3):144-9. doi: 10.1053/j.sempedsurg.2016.02.007.
- Schweiger C, Cohen AP, Rutter MJ. Tracheal and bronchial stenoses and other obstructive conditions. *J Thorac Dis.* 2016;8(11):3369-78. doi: 10.21037/jtd.2016.11.74.
- Miyahara J, Ohhashi T, Nakashima H, Sugiura H, Ohki S. Successful management of acquired left bronchial stenosis caused by massive atelectasis. *SAGE Open Med Case Rep.* 2019;7:2050313X1983817. doi: 10.1177/2050313X19838170.
- Marini T, Hobbs SK, Chaturvedi A, Kaproth-Joslin K. Beyond bronchitis: a review of the congenital and acquired abnormalities of the bronchus. *Insights Imaging.* 2017;8(1):141-53. doi: 10.1007/s13244-016-0537-y.
- Kut A, Cakir E, Gokdemir Y, Midyat L, Ersu R, Erdem E, et al. Intrinsic Endobronchial Obstructions in Children from Turkey: Evaluation of 2,555 Flexible Bronchoscopic Procedures. *Respiration.* 2013;85(1):43-8. doi: 10.1159/000342339.
- Poupalou A, Varetti C, Lauron G, Steyaert H, Valla JS. Perinatal diagnosis and management of congenital bronchial stenosis or atresia: 4 cases. *J Thorac Cardiovasc Surg.* 2011;141(1):e11-4. doi: 10.1016/j.jtcvs.2010.09.046.
- Kiener A, Anderson A, Thomas A. Congenital Bronchial Stenosis Presenting as Neonatal Respiratory Distress: A Case Report. *J Emerg Med.* 2020;58(2):e83-6. doi: 10.1016/j.jemermed.2019.10.008.
- Hofferberth SC, Watters K, Rahbar R, Fynn-Thompson F. Management of Congenital Tracheal Stenosis. *Pediatrics.* 2015;136(3):e660-9. doi: 10.1542/peds.2014-3931.
- Moriuchi Y, Fuchigami T, Mizukoshi W, Morioka I. An Infant With Congenital Tracheal and Bronchial Stenosis Diagnosed by Chest Three-Dimensional Computed Tomography. *Cureus.* 2022; 14(5):e24771. doi: 10.7759/cureus.24771.
- Hoppe H, Dinkel HP, Walder B, von Allmen G, Gugger M, Vock P. Grading airway stenosis down to the segmental level using virtual bronchoscopy. *Chest.* 2004;125(2):704-11. doi: 10.1378/chest.125.2.704.
- Chao YC, Peng CC, Lee KS, Lin SM, Chen MR. The association of congenital tracheobronchial stenosis and cardiovascular anomalies. *Int J Pediatr Otorhinolaryngol.* 2016;83:1-6. doi: 10.1016/j.ijporl.2016.01.024.

12. Sommburg O, Helling-Bakki A, Alrajab A, Schenk JP, Springer W, Mall MA, et al. Assessment of Suspected Vascular Rings and Slings and/or Airway Pathologies Using Magnetic Resonance Imaging Rather Than Computed Tomography. *Respiration*. 2019;97(2):108-18. doi: 10.1159/000492080.
13. Georgopoulos R, Hill C, Heinle JS, Mehta D. Congenital right bronchial stenosis with high bifurcation: Successful management with side to side tracheobronchial anastomosis. *Int J Pediatr Otorhinolaryngol*. 2018;111:180-2. doi: 10.1016/j.ijporl.2018.06.011.
14. Van Klaveren RJ, Morshuis WJ, Lacquet LK, Cox AL, Festen J, Heystraten FM. Congenital bronchial atresia with regional emphysema associated with pectus excavatum. *Thorax*. 1992;47(12):1082-3. doi: 10.1136/thx.47.12.1082.
15. Ando M, Ichimori Y, Sakamoto S. Vascular compression of the left bronchus in a patient with funnel chest. *Gen Thorac Cardiovasc Surg*. 2020;68(12):1555-7. doi: 10.1007/s11748-020-01341-2.
16. Andrews TM, Myer CM, Gray SP. Abnormalities of the bony thorax causing tracheobronchial compression. *Int J Pediatr Otorhinolaryngol*. 1990;19(2):139-44. doi: 10.1016/0165-5876(90)90219-h.
17. Donnelly LF, Bisset GS. Airway compression in children with abnormal thoracic configuration. *Radiology*. 1998;206(2):323-6. doi: 10.1148/radiology.206.2.9457181
18. Kumar V, Chhapola V, Deepthi B, Kanwal S, Sharma A. Chondrodysplasia punctata with severe airway stenosis. *Indian J Crit Care Med*. 2018;22(7):552-4. doi: 10.4103/ijccm.IJCCM_105_18.
19. Chan JL, Yap KH, Teoh OH, Nakao M. Combination of slide tracheoplasty and side-to-side bronchoplasty for complex congenital tracheobronchial stenosis. *Interact Cardiovasc Thorac Surg*. 2021;33(1):155-7. doi: 10.1093/icvts/ivab058.
20. Antón-Pacheco JL, Galletti L, Cabezalí D, Luna C, González De Orbe G, Sánchez-Solis De Querol M. Management of bilateral congenital bronchial stenosis in an infant. *J Pediatr Surg*. 2007;42(11):e1-3. doi: 10.1016/j.jpedsurg.2007.08.043.
21. Grillo HC, Wright CD, Vlahakes GJ, MacGillivray TE. Management of congenital tracheal stenosis by means of slide tracheoplasty or resection and reconstruction, with long-term follow-up of growth after slide tracheoplasty. *J Thorac Cardiovasc Surg*. 2002;123(1):145-52. Available from: <https://linkinghub.elsevier.com/retrieve/pii/S0022522302040096>. Accessed: Apr 29, 2024.
22. Yeh YT, Liu C, Tsai HL, Wu FY, Soong WJ, Lee YS, et al. A combination of tracheoplasty and tracheal stenting is an acceptable method of treating severe congenital tracheobronchial stenosis under extracorporeal membrane oxygenation. *J Pediatr Surg*. 2019;54(12):2492-7. doi: 10.1016/j.jpedsurg.2019.08.043.