

## REVIEW

# Lung malformations: predicting respiratory distress at birth

Ernst Eber

## Correspondence to:

ernst.eber@medunigraz.at. ORCID: <https://orcid.org/0000-0001-7628-030X>**ABSTRACT**

A number of classifications and nomenclatures have been suggested for lung malformations based on the heterogeneous appearances of these abnormalities, and “congenital thoracic malformation” has been recommended as an umbrella term for the whole spectrum of developmental lung and thoracic abnormalities. With the implementation and improvement of prenatal ultrasound examinations it appears that the incidence of lung malformations has risen over the last decades. In developed countries, the vast majority of lung malformations are detected in prenatal screening programmes. Clinical features of lung malformations vary widely. The majority of fetuses have a good outcome, with typically less than 20% of neonates presenting with early life manifestations including neonatal respiratory distress and respiratory insufficiency. Respiratory distress at birth is predicted by size, not the type of a lung malformation. Studies on the natural history of prenatally detected lung malformations have shown that many lesions decrease in size over time; even full prenatal regression of malformations has been described. A number of variables have been investigated as potential predictors of neonatal respiratory distress and early surgery. The most extensively studied parameter is the congenital pulmonary airway malformation (CPAM) volume ratio (CVR), which represents a volumetric index of mass size allowing for comparisons of fetuses at different gestational ages. In addition, other ultrasound and magnetic resonance imaging (MRI) derived measurements such as maximal (cyst) volume, mass to thorax ratio, observed to expected normal fetal lung volume, fetal cardiac axis, and cardiac position have been investigated. CVR has been associated with the development of hydrops, neonatal respiratory distress in both term and preterm infants, and the need for respiratory support within 24 hours after birth. While consensus on a cut-off value is lacking, it appears that a CVR at presentation of <0.40 is associated with favorable outcomes. However, a low CVR does not completely rule out respiratory problems after birth. A multidisciplinary approach to the management of fetuses and infants with lung malformations is important, and fetuses at risk should be delivered at specialized tertiary care centers with a neonatal intensive care unit and pediatric surgical expertise to ensure optimal clinical outcomes.

**IMPACT STATEMENT:** A congenital pulmonary airway malformation volume ratio (CVR) at presentation of <0.40 has been associated with favourable outcomes.

**Doi**

10.56164/PediatrRespirJ.2024.56

Division of Pediatric Pulmonology and Allergology, Department of Pediatrics and Adolescent Medicine, Medical University of Graz, Graz, Steiermark, Austria

**KEY WORDS**

*Lung malformations; congenital thoracic malformations; prenatal ultrasound examinations; natural history; clinical features.*

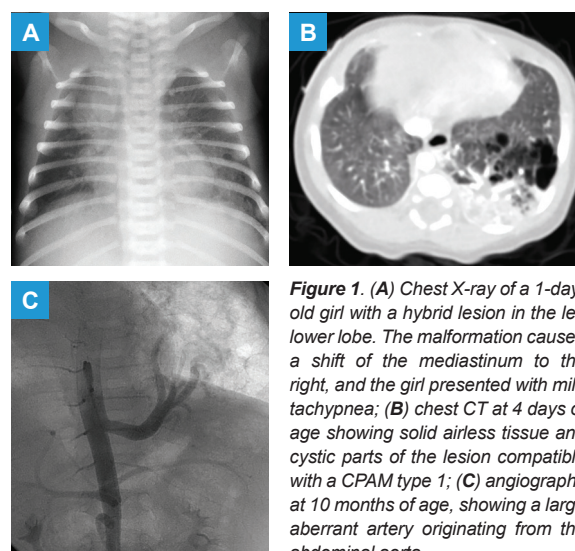
## NOMENCLATURE

The term ‘congenital thoracic malformation’ (CTM) has been recommended as an umbrella term for all congenital lung and thoracic malformations (1). It comprises a spectrum of developmental abnormalities, including pulmonary parenchymal lesions such as congenital cystic adenomatoid malformation (CCAM) or congenital pulmonary airway malformation (CPAM), extra- and intralobar bronchopulmonary sequestration, and congenital lobar and segmental emphysemas, as well as less frequent abnormalities such as bronchogenic and foregut duplication cysts (2, 3).

The original Stocker classification distinguished three CCAM types, 1, 2, and 3: in the ‘macrocytic type’ 1) one or more large cysts predominate; the ‘microcytic type’ 2) consists of numerous small cysts; and the ‘solid type’ 3) is characterized by a mass of airless tissue (4). Subsequently, Stocker proposed a new name for these lesions – CPAM – and also the rarer types 0 and 4: type 0 is a tracheobronchial defect (also known as acinar dysplasia), characterized by firm small lungs with a bronchial airway; type 4 is an entirely alveolar defect at the lung periphery (5). Of the five types, only types 1, 2, and 4 are cystic, and only types 1, 2, and 3 are adenomatoid. **Table 1** summarizes the characteristics of this classification.

However, the nomenclature of lung malformations is quite confusing (1). A number of classifications and nomenclatures have been suggested, based on the heterogeneous appearances of the malformations (5-7). The

term ‘hybrid lesion’ refers to a CTM with anatomical and/or histological overlap between a CCAM and a bronchopulmonary sequestration, such as a lesion with an abnormal blood supply and a histological appearance compatible with CCAM (**Figure 1A, B, C**). CTMs presumably share a common embryological origin and represent a spectrum of abnormalities of fetal lung development with significant overlap, and airway obstruction *in utero* might result in defective lung development, with different patterns of lung malformations according to the level, timing, and degree of the obstruction (7). While there is histological evidence for an association of peripheral bronchial atresia or stenosis with all types of CTMs, mode and timing of these incidents are unclear (8, 9).



**Figure 1.** (A) Chest X-ray of a 1-day-old girl with a hybrid lesion in the left lower lobe. The malformation caused a shift of the mediastinum to the right, and the girl presented with mild tachypnea; (B) chest CT at 4 days of age showing solid airless tissue and cystic parts of the lesion compatible with a CPAM type 1; (C) angiography at 10 months of age, showing a large aberrant artery originating from the abdominal aorta.

**Table 1.** Classification of congenital pulmonary airway malformations according to Stocker (1, 5).

Type	Incidence	Cyst size	Histology
0	Rare		Complete failure of development beyond the pseudo-glandular stage (acinar dysplasia); lethal.
1	Common	Large cysts (>2 cm), can be multiple	Pseudostratified ciliated columnar epithelium, intermixed with rows of mucous cells.
2	Common	Multiple small cysts, sponge-like	Dilated bronchiole-like structures, intermixed with simplified alveolar parenchyma; occasionally striated muscle.
3	Rare	Solid	Bronchiolar structures separated by small air spaces with cuboidal lining, resembling late fetal lung.
4	Rare	Large cysts	Peripheral and thin-walled cysts, lined by alveolar or bronchiolar epithelial cells upon loose mesenchymal tissue.

## EPIDEMIOLOGY

In 1979, the European Community established the European Surveillance of Congenital Anomalies (EUROCAT), with the aim to establish a network of population-based registers for the epidemiological surveillance of congenital anomalies (10). This network consists of 43 registries in 23 countries and covers approximately 30% of the European birth population. However, in most cases the individual registers are regional and not national, which is likely to affect robustness of the data. In past years, the reported incidence was around 4/10,000 live births for all CTMs and around 1/10,000 live births for CCAMs, respectively (10). The reported incidence of bronchopulmonary sequestrations ranges between 1 and 6% of all CTMs. It appears that the incidence of CTMs has risen over the last decades, partially explained by the implementation and improvement of prenatal fetal ultrasound examinations (11). For low- and middle-income countries there is a lack of epidemiological data.

## PRENATAL DETECTION AND POSTNATAL EVALUATION

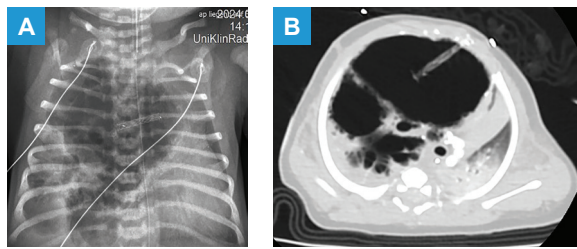
In developed countries, more than 90% of lung malformations are detected in prenatal screening programmes. Many of these lesions will have regressed and some even disappeared on postnatal ultrasound and chest X-ray examinations. Vanishing lung lesions late in gestation have been reported to be associated with a low CCAM or CPAM volume ratio (CVR), a volumetric index of mass size allowing for comparisons of fetuses at different gestational ages, and microcystic disease (12). Postnatal evaluation including ultrasound with Doppler, chest X-ray, and chest computed tomography (CT) scan with intravenous contrast or magnetic resonance imaging (MRI) is required in all children with prenatally detected CTMs. These investigations are intended to characterise the malformation, its vascularity, and whether a communication with the tracheo-bronchial tree is present. Chest CT angiography in the first year of life is considered the gold standard for specifying CTM characteristics (13); in asymptomatic children it is usually performed in the second half of the first year of life. However, while clinicians often try to make a pathological diagnosis on imaging, modalities including ultrasound, CT and MRI all have some level of discrepancy with pathology (14, 15). To rule out a

foregut communication, an esophageal contrast study may be necessary. Further, all children should be evaluated for associated congenital disorders, in particular cardiac anomalies (2).

## CLINICAL FEATURES AND COMPLICATIONS

Clinical features of CTMs vary widely. *In utero*, large lesions may compress the ipsilateral lung and via mediastinal shift also the contralateral lung, resulting in lung hypoplasia. Compression of the esophagus may lead to polyhydramnios, and the resulting distension of the uterus may induce premature labor. Impairment of venous return and hydrops may bring about fetal or neonatal death. However, treatment *in utero* is only required in a minority of fetuses, with interventions such as maternal steroid administration, puncture or shunting of macrocystic masses, alcohol embolization or lasering of a feeding vessel, lobectomy via hysterotomy for more solid masses, and resection while on placental circulation. A fetal hydrothorax or pleural effusion may be treated with thoraco-amniotic shunting. Fetal therapy requires the expertise of a highly skilled multidisciplinary team (1, 2). The majority of fetuses with CTMs have a good outcome with typically less than 20% of neonates presenting with early life manifestations including respiratory distress and respiratory insufficiency, cardiovascular overload, or pneumothorax (**Figure 2A, B**) (1, 16, 17). However, primarily asymptomatic neonates may develop complications at any age from infancy to adulthood; the exact incidence of complications and the natural history of different types of CTMs are largely unknown. Complications include infection (recurrent localized pneumonia, lung abscess, empyema), hemoptysis, pneumothorax (due to cyst rupture), compression of neighbouring structures (airways, esophagus), sudden respiratory compromise, and cardiovascular symptoms or high output cardiac failure (if there is a large systemic arterial blood supply) (1, 3, 18-23).

In addition, relationships between CTMs and malignancies have repeatedly been reported. These include pleuropulmonary blastoma (typically, preschool children are affected) and bronchioloalveolar carcinoma (the mean age for this complication appears to be young adulthood) (24-26). In a series of prenatally detected, asymptomatic cystic malformations almost a quarter demonstrated either subclinical infection or malignancy (27).



**Figure 2.** (A) Chest X-ray and (B) chest CT of an intubated 38-week gestational age boy with a CPAM type 1 demonstrating very large cysts, which compressed the surrounding lung tissue and caused a shift of the mediastinum to the left, and the remnant of a thoraco-amniotic shunt. The boy presented with severe respiratory distress and respiratory insufficiency immediately after birth.

### NATURAL HISTORY OF PRENATALLY DETECTED CTMS

There is still a shortage of prospective studies on the natural history of prenatally detected CTMs. Many lesions decrease in size over time, but for the individual malformation the growth process is unpredictable. Hydrops is associated with an extremely high risk of fetal or neonatal death, but an initially large lesion does not necessarily correlate with a poor prognosis (2).

Crombleholme *et al.* introduced CVR as a sonographic indicator of fetuses at risk for hydrops who require close ultrasound observation and possible fetal intervention. They controlled for fetal gestational age by dividing the volume of the malformation by the head circumference ( $CVR = L \times W \times H \times 0.52 / \text{head circumference}$ ). Thus, CVR allows direct comparisons of fetuses at different gestational ages and serial measurements of the lung malformation in the same fetus normalized to head circumference, to determine progression or regression of the malformation (28).

Riley *et al.* from the same center performed a retrospective review of the pre- and postnatal courses of 103 fetuses with an intralobar ( $n = 44$ ) or extralobar ( $n = 59$ ) bronchopulmonary sequestration managed at their institution. They found that most extralobar (71%) and intralobar (94%) sequestrations decreased in size or became isoechoic from initial to final evaluation. The peak lesion size occurred at 26 to 28 weeks gestation (29).

Delacourt *et al.* conducted a nationally representative, multicenter, prospective cohort study including 579 ultrasound examinations in 176 pregnant women with a diagnosis of congenital pulmonary malformations. Several ultrasound examinations performed between diag-

nosis and delivery included CVR measurements, with changes in CVR modelled as a function of gestational age, overall and separate for cystic/mixed vs. hyperechoic malformations. Further, the association between CVR and signs of compression during pregnancy was examined (30). They found a statistically significant decrease in CVR with increasing gestational age, with a different pattern of change according to the phenotype of the malformation at the first ultrasound examination. While cystic/mixed malformations were characterized by a steady decrease in CVR with increasing gestational age, hyperechoic malformations showed an initial increase in CVR up to 27 weeks of gestation, followed by a subsequent decrease. For cystic/mixed malformations, peak CVR values were predicted as early as 21-22 weeks, compared to 25-26 weeks for hyperechoic malformations. The authors speculated that this difference might be the result of different pathophysiological mechanisms or differences in the timing of occurrence of different types of malformations. Further, CVR measured at the first ultrasound examination was found to be strongly associated with the odds of subsequent compression (30).

### PREDICTION OF RESPIRATORY DISTRESS AT BIRTH

In the last 20 years, a number of variables have been investigated as potential predictors of neonatal respiratory distress and early surgery, with CVR being the most extensively studied parameter.

In a retrospective single center study, Hellmund *et al.* evaluated the potential of prenatal sonographic findings as risk parameters for adverse outcome or need for intervention in fetuses with a CPAM (31). The Authors performed measurements of CVR, mass to thorax ratio (MTR), and observed to expected lung to head ratio (o/e LHR) and correlations to fetal or neonatal morbidity and mortality, and/or need for prenatal intervention. They came to the conclusion, that CVR and MTR are able to identify fetuses at risk, and that the o/e LHR is less sensitive than the other two parameters.

Similarly, in a retrospective single center study Girsén *et al.* evaluated the utility of fetal lung mass imaging for predicting neonatal respiratory distress by analysing the initial as well as maximal lung mass volume and CVR determined by sonography and MRI (32).

They reported the strongest predictors of respiratory distress to be maximal volume  $>24.0 \text{ cm}^3$  by MRI and maximal volume  $>34.0 \text{ cm}^3$  by sonography.

In another retrospective single center study of children with prenatal diagnosis of a lung malformation, Gerall *et al.* assessed fetal ultrasound and MRI parameters including maximal CVR, absolute cyst volume, and observed to expected normal fetal lung volume (o/e NFLV) (33). They found a correlation between postnatal respiratory symptoms and ultrasound based, but not with MRI derived measurements.

Further, Tuzovic *et al.* again in a retrospective study set out to assess the performance of the fetal cardiac axis (CA) and/or cardiac position (CP) versus the CVR in predicting any and severe neonatal respiratory morbidity in fetal congenital lung malformations (34). They reported an abnormal CA and/or CP to have a higher sensitivity for any respiratory morbidity compared to the CVR (with cut-off values of 0.5 and 0.8, respectively) both before 24 weeks and between 24 and 32 weeks.

### CPAM VOLUME RATIO (CVR)

In the early years of this millennium, reported threshold values of CVR ranged between 1.6 and 2.0 (28, 35, 36). Ehrenberg-Buchner *et al.* conducted a retrospective review of 64 fetal lung lesions managed at a single fetal care referral center. Ultrasound data were correlated with perinatal outcomes (37). Among 60/64 fetuses without hydrops, the CVR was the only variable that was significantly associated with respiratory compromise and the need for lung resection at birth. Based on a maximum CVR  $>1.0$ , the sensitivity, specificity, positive predictive value, and negative predictive value for respiratory morbidity were 90%, 93%, 75%, and 98%, respectively.

Ruchonnet-Metrailler *et al.* investigated cases with prenatal diagnosis of hyperechoic and/or cystic lung lesions from RespiRare, the French prospective multicenter registry for liveborn children with rare respiratory diseases and sought correlations between prenatal parameters and neonatal respiratory outcome (16). Twenty-two out of 89 children had abnormal breathing at birth, and severe respiratory distress was observed in 12 neonates. While respiratory distress was significantly associated with mediastinal shift, polyhydramnios, ascites, maximum prenatal malformation area, and

maximum CVR, severe respiratory distress was best predicted by polyhydramnios, ascites, or a CVR  $>0.84$ . By way of contrast, Costanzo *et al.* in a retrospective, single center study of 70 prenatally diagnosed fetuses with pulmonary malformations referred to their center reported the presence of fetal complications and a CVR  $>1.6$  as predictors of respiratory distress at birth and of the need for early surgery (38).

More recently, Kane *et al.* performed a retrospective cohort study of all pregnancies with a prenatal diagnosis of an isolated fetal echogenic lung lesion managed at their referral center between 2005 and 2015 (39). In 65 cases (four with hydrops), they found a CVR at presentation of  $<0.45$  to be associated with favorable outcomes.

In the same year, Eyerly-Webb *et al.* in a retrospective multicenter study used serial measurements to create estimated growth curves of fetal CVR for both asymptomatic and symptomatic neonates with lung malformations, in order to investigate whether a discriminant prognostic model could accurately predict which fetuses will require invasive respiratory support at delivery (40). Sixteen out of 147 neonates required postnatal invasive respiratory support. Fetal CVR growth curves showed different growth patterns for asymptomatic vs. symptomatic neonates; CVR was significantly higher in symptomatic neonates, and values peaked at around 25 weeks' gestation in asymptomatic neonates.

In another retrospective single center study, Peters *et al.* analyzed prenatal, perinatal and postnatal data from fetuses with a lung malformation (41). Fourteen out of 80 fetuses required respiratory support on the first postnatal day, and 17 required surgery within 2 years. The Authors found a CVR at  $25 + 0$  to  $29 + 6$  weeks predictive of the need for respiratory support, with a cut-off value of 0.39. However, they also showed that even full prenatal regression of a malformation does not rule out respiratory problems after birth. Altogether, there was only low concordance between the prenatal appearance of the malformations and the postnatal type.

Delacourt *et al.* utilized a prospective population-based nationally representative cohort to develop a simple prognostic model for predicting the risk of neonatal respiratory distress in preterm and term infants with lung malformations (42). They used CVR measured at diagnosis and the highest CVR measured as main

predictive variables. Sixty-seven out of 383 neonates had respiratory distress. For term infants, the most parsimonious model included the highest CVR measured as the only predictive variable. The probability of neonatal respiratory distress increased linearly with increasing maximum CVR and remained below 10% for a maximum CVR <0.4. For preterm infants, maximum CVR and gestational age were found to be predictors of neonatal respiratory distress.

## CONCLUSIONS

A minority of fetuses present with a neonatal respiratory distress and respiratory insufficiency. Respiratory distress at birth is predicted by size, not the type of a lung malformation. Several parameters have been investigated as potential predictors of neonatal respiratory distress and/or early surgery. The most commonly used parameter CVR among others has been associated with neonatal respiratory distress and early need of respiratory support. In recent years, a CVR at presentation of <0.40 has been associated with favorable outcomes. Importantly, prenatal regression of a lung malformation or a low CVR do not rule out respiratory problems after birth. The value of other sonography or MRI-derived parameters in individualized risk assessment to guide decisions is being discussed. A multidisciplinary approach to the management of lung

malformations is key, and fetuses at risk should be delivered at specialized tertiary care centers to ensure best possible clinical outcomes.

## COMPLIANCE WITH ETHICAL STANDARDS

### Conflict of interests

The Author has declared no conflict of interests.

### Financial support

There was no institutional or private funding for this article.

### Author contributions

EE wrote the manuscript.

### Ethical approval

#### Human studies and subjects

N/A.

#### Animal studies

N/A.

### Data sharing and data accessibility

Data are available upon motivated request to the Corresponding Author.

### Publication ethics

#### Plagiarism

Authors declare no potentially overlapping publications with the content of this manuscript and all original studies are cited as appropriate.

#### Data falsification and fabrication

All the data correspond to the real.

## REFERENCES

- Kotecha S, Barbato A, Bush A, Claus F, Davenport M, Delacourt C, et al. Antenatal and postnatal management of congenital cystic adenomatoid malformation. *Paediatr Respir Rev*. 2012;13(3):162-70. doi: 10.1016/j.prrv.2012.01.002.
- Eber E. Antenatal diagnosis of congenital thoracic malformations: early surgery, late surgery, or no surgery? *Semin Respir Crit Care Med*. 2007;28(3):355-66. doi: 10.1055/s-2007-981656.
- Davenport M, Eber E. Long term respiratory outcomes of congenital thoracic malformations. *Semin Fetal Neonatal Med*. 2012;17(2):99-104. doi: 10.1016/j.siny.2012.01.011.
- Stocker JT, Madewell JE, Drake RM. Congenital cystic adenomatoid malformation of the lung. Classification and morphologic spectrum. *Hum Pathol*. 1977;8(2):155-71. doi: 10.1016/s0046-8177(77)80078-6.
- Stocker JT. Congenital pulmonary airway malformation: a new name and expanded classification of congenital cystic adenomatoid malformation of the lung. *Histopathology*. 2002;41(Suppl 2):424-31.
- Bush A. Congenital lung disease: a plea for clear thinking and clear nomenclature. *Pediatr Pulmonol*. 2001;32(4):328-37. doi: 10.1002/ppul.1126.
- Langston C. New concepts in the pathology of congenital lung malformations. *Semin Pediatr Surg*. 2003;12(1):17-37. doi: 10.1053/spsu.2003.00001.
- Kunisaki SM, Fauza DO, Nemes LP, Barnewolt CE, Estroff JA, Kozakewich HP, et al. Bronchial atresia: the hidden pathology within a spectrum of prenatally diagnosed lung masses. *J Pediatr Surg*. 2006;41(1):61-5. doi: 10.1016/j.jpedsurg.2005.10.082.
- Dehner LP, Schultz KAP, Hill DA. Congenital pulmonary airway malformations with a reconsideration and current perspective on the Stocker classification. *Pediatr Dev Pathol*. 2023;26(3):241-9. doi: 10.1177/10935266221146823.
- EUROCAT: European Surveillance of Congenital Anomalies. Available from: [www.eurocat-network.eu/](http://www.eurocat-network.eu/). Accessed: Sept 26, 2024.
- Stocker LJ, Wellesley DG, Stanton MP, Parasuraman R, Howe DT. The increasing incidence of foetal echo-

- genic congenital lung malformations: an observational study. *Prenat Diagn.* 2015;35(2):148-53. doi: 10.1002/pd.4507.
12. Kunisaki SM, Ehrenberg-Buchner S, Dillman JR, Smith EA, Mychaliska GB, Treadwell MC. Vanishing fetal lung malformations: Prenatal sonographic characteristics and postnatal outcomes. *J Pediatr Surg.* 2015;50(6):978-82. doi: 10.1016/j.jpedsurg.2015.03.025.
  13. Tivnan P, Winant AJ, Epelman M, Lee EY. Pediatric congenital lung malformations: Imaging guidelines and recommendations. *Radiol Clin N Am.* 2022;60(1):41-54. doi: 10.1016/j.rcl.2021.08.002.
  14. Narayan RR, Abadilla N, Greenberg DR, Sylvester KG, Hintz SR, Barth RA, et al. Predicting pathology from imaging in children undergoing resection of congenital lung lesions. *J Surg Res.* 2019;236:68-73. doi: 10.1016/j.jss.2018.10.042.
  15. Mon RA, Johnson KN, Ladino-Torres M, Heider A, Mychaliska GB, Treadwell MC, et al. Diagnostic accuracy of imaging studies in congenital lung malformations. *Arch Dis Child Fetal Neonatal Ed.* 2019;104(4):F372-F377. doi: 10.1136/archdischild-2018-314979.
  16. Ruchonnet-Mettrailler I, Leroy-Terquem E, Stirnemann J, Cros P, Ducoin H, Hadchouel A, et al. Neonatal outcomes of prenatally diagnosed congenital pulmonary malformations. *Pediatrics.* 2014;133(5):e1285-91. doi: 10.1542/peds.2013-2986.
  17. Cook J, Chitty LS, De Coppi P, Ashworth M, Wallis C. The natural history of prenatally diagnosed congenital cystic lung lesions: long-term follow-up of 119 cases. *Arch Dis Child.* 2017;102(9):798-803. doi: 10.1136/archdischild-2016-311233.
  18. Baird R, Puligandla PS, Laberge JM. Congenital lung malformations: informing best practice. *Semin Pediatr Surg.* 2014;23(5):270-7. doi: 10.1053/j.sempedsurg.2014.09.007.
  19. Stanton M, Njere I, Ade-Ajayi N, Patel S, Davenport M. Systematic review and meta-analysis of the postnatal management of congenital cystic lung lesions. *J Pediatr Surg.* 2009;44(5):1027-33. doi: 10.1016/j.jpedsurg.2008.10.118.
  20. Kapralik J, Wayne C, Chan E, Nasr A. Surgical versus conservative management of congenital pulmonary airway malformation in children: A systematic review and meta-analysis. *J Pediatr Surg.* 2016;51(3):508-12. doi: 10.1016/j.jpedsurg.2015.11.022.
  21. Criss CN, Musili N, Matusko N, Baker S, Geiger JD, Kunisaki SM. Asymptomatic congenital lung malformations: Is nonoperative management a viable alternative? *J Pediatr Surg.* 2018;53(6):1092-7. doi: 10.1016/j.jpedsurg.2018.02.065.
  22. Karlsson M, Conner P, Ehren H, Bitkover C, Burgos CM. The natural history of prenatally diagnosed congenital pulmonary airway malformations and bronchopulmonary sequestrations. *J Pediatr Surg.* 2022;57(10):282-7. doi: 10.1016/j.jpedsurg.2022.03.021.
  23. Goussard P, Eber E, Venkatakrishna S, Janson J, Schubert P, Andronikou S. Bronchoscopy findings in children with congenital lung and lower airway abnormalities. *Paediatr Respir Rev.* 2024;49:43-61. doi: 10.1016/j.prrv.2023.10.001.
  24. Nasr A, Himidan S, Pastor AC, Taylor G, Kim PC. Is congenital cystic adenomatoid malformation a premalignant lesion for pleuropulmonary blastoma? *J Pediatr Surg.* 2010;45(6):1086-9. doi: 10.1016/j.jpedsurg.2010.02.067.
  25. Hermelijn SM, Wolf JL, Dorine den Toom T, Wijnen RMH, Rottier RJ, Schnater JM, et al. Early KRAS oncogenic driver mutations in non-mucinous tissue of congenital pulmonary airway malformations as an indicator of potential malignant behavior. *Hum Pathol.* 2020;103:95-106. doi: 10.1016/j.humpath.2020.07.015.
  26. Muntean A, Baniyas LE, Ade-Ajayi N, Patel SB, McKinney O, Davenport M. Neonatal congenital pulmonary airway malformation associated with mucinous adenocarcinoma and KRAS mutations. *J Pediatr Surg.* 2022;57(11):520-6. doi: 10.1016/j.jpedsurg.2021.12.018.
  27. Durell J, Thakkar H, Gould S, Fowler D, Lakhoo K. Pathology of asymptomatic, prenatally diagnosed cystic lung malformations. *J Pediatr Surg.* 2016;51(2):231-5. doi: 10.1016/j.jpedsurg.2015.10.061.
  28. Crombleholme TM, Coleman B, Hedrick H, Liechty K, Howell L, Flake AW, Johnson M, Adzick NS. Cystic adenomatoid malformation volume ratio predicts outcome in prenatally diagnosed cystic adenomatoid malformation of the lung. *J Pediatr Surg.* 2002;37(3):331-8. doi: 10.1053/jpsu.2002.30832.
  29. Riley JS, Urwin JW, Oliver ER, Coleman BG, Khalek N, Moldenhauer JS, et al. Prenatal growth characteristics and pre/postnatal management of bronchopulmonary sequestrations. *J Pediatr Surg.* 2018;53(2):265-9. doi: 10.1016/j.jpedsurg.2017.11.020.
  30. Delacourt C, Bertille N, Salomon LJ, Benachi A, Henry E, Massardier J, et al.; Prenatal MALFPULM Study Group. Prenatal natural history of congenital pulmonary malformations: MALFPULM population-based cohort study. *Ultrasound Obstet Gynecol.* 2019;54(3):381-8. doi: 10.1002/uog.20130.
  31. Hellmund A, Berg C, Geipel A, Bludau M, Heydweiller A, Bachour H, et al. Prenatal diagnosis and evaluation of sonographic predictors for intervention and adverse outcome in congenital pulmonary airway malformation. *PLoS One.* 2016;11(3):e0150474. doi: 10.1371/journal.pone.0150474.
  32. Girsan AI, Hintz SR, Sammour R, Naqvi A, El-Sayed YY, Sherwin K, et al. Prediction of neonatal respiratory distress in pregnancies complicated by fetal lung masses. *Prenat Diagn.* 2017;37(3):266-72. doi: 10.1002/pd.5002.
  33. Gerall C, Chumdermpadestuk R, Jacobs S, Weijia F, Maddocks A, Ayyala R, et al. Prenatal ultrasound- and MRI-based imaging predictors of respiratory symptoms at birth for congenital lung malformations. *J Pediatr Surg.* 2023;58(3):420-6. doi: 10.1016/j.jpedsurg.2022.08.026.

34. Tuzovic L, Copel JA, Stitelman DH, Levit O, Bahtiyar MO. Utility of fetal cardiac axis and cardiac position assessment in predicting neonatal respiratory morbidity in fetal congenital lung lesions. *J Ultrasound Med.* 2019;38(9):2361-72. doi: 10.1002/jum.14931.
35. Curran PF, Jelin EB, Rand L, Hirose S, Feldstein VA, Goldstein RB, et al. Prenatal steroids for microcystic congenital cystic adenomatoid malformations. *J Pediatr Surg.* 2010;45(1):145-50. doi: 10.1016/j.jpedsurg.2009.10.025.
36. Cass DL, Olutoye OO, Cassady CI, Moise KJ, Johnson A, Papanna R, et al. Prenatal diagnosis and outcome of fetal lung masses. *J Pediatr Surg.* 2011;46(2): 292-8. doi: 10.1016/j.jpedsurg.2010.11.004.
37. Ehrenberg-Buchner S, Stapf AM, Berman DR, Dronowski RA, Mychaliska GB, Treadwell MC, et al. Fetal lung lesions: can we start to breathe easier? *Am J Obstet Gynecol.* 2013;208(2):151.e1-7. doi: 10.1016/j.ajog.2012.11.012.
38. Costanzo S, Filisetti C, Vella C, Rustico M, Fontana P, Lista G, et al. Pulmonary malformations: predictors of neonatal respiratory distress and early surgery. *J Neonat Surg.* 2016;5(3):27. doi: 10.21699/jns.v5i3.375.
39. Kane SC, Da Silva Costa F, Cramer JA, Reidy KL, Kaganov H, Palma-Dias R. Antenatal assessment and postnatal outcome of fetal echogenic lung lesions: a decade's experience at a tertiary referral hospital. *J Matern Fetal Neonatal Med.* 2019;32(5):703-9. doi: 10.1080/14767058.2017.1388367.
40. Eyerly-Webb S, Nicolas CT, Watson D, Dion E, Amin R, Wagner AJ, et al. Dynamic discriminant model for predicting respiratory distress at birth based on mass volume ratio in fetuses with congenital lung malformation. *Ultrasound Obstet Gynecol.* 2019;54(6):759-66. doi: 10.1002/uog.20255.
41. Peters NCJ, Hijkoop A, Hermelijn SM, van Schoonhoven MM, Eggink AJ, van Rosmalen J, et al. Prediction of postnatal outcome in fetuses with congenital lung malformation: 2-year follow-up study. *Ultrasound Obstet Gynecol.* 2021;58(3):428-38. doi: 10.1002/uog.23542.
42. Delacourt C, Bertille N, Salomon LJ, Rahshenas M, Benachi A, Bonnard A, et al., for the MALFPULM study group. Predicting the risk of respiratory distress in newborns with congenital pulmonary malformations. *Eur Respir J.* 2022;59(2):2100949. doi: 10.1183/13993003.00949-2021.